Lymphatic System: Overview

- Consists of two semi-independent parts:
  - A network of lymphatic vessels
  - Lymphoid tissues and organs scattered throughout the body
- Returns interstitial fluid and leaked plasma proteins back to the blood
- Lymph – interstitial fluid once it has entered lymphatic vessels

- **Lymphatic System**
  - **Made up of:**
    - **Lymph**
    - **Lymph vessels**
    - **Lymphocytes**
    - **Lymph nodules**
    - **Lymph nodes**
    - **Tonsils**
    - **Spleen**
    - **Thymus Gland**
    - **Red Bone Marrow**
  - **Functions**
    - **Maintains fluid balance in tissues**
    - **Absorbs fats from the small intestine**
    - **Defends against microorganisms and foreign substances**

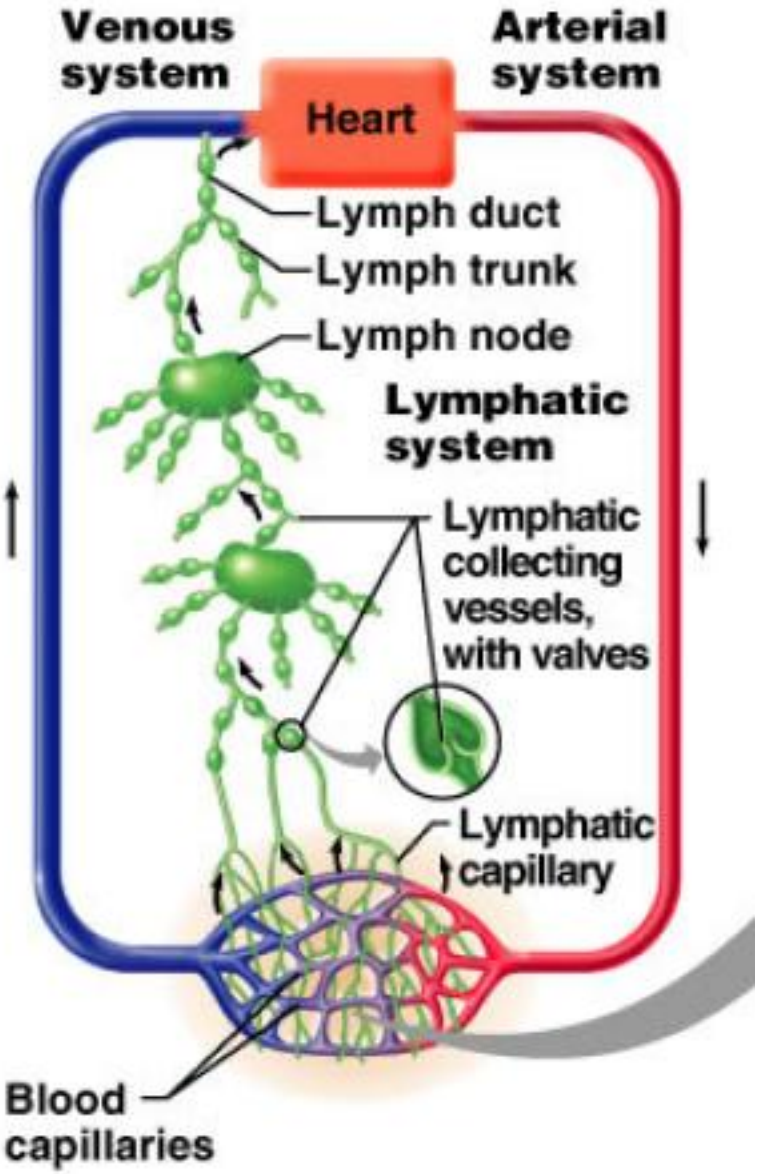

• Lymph Trunks and Ducts

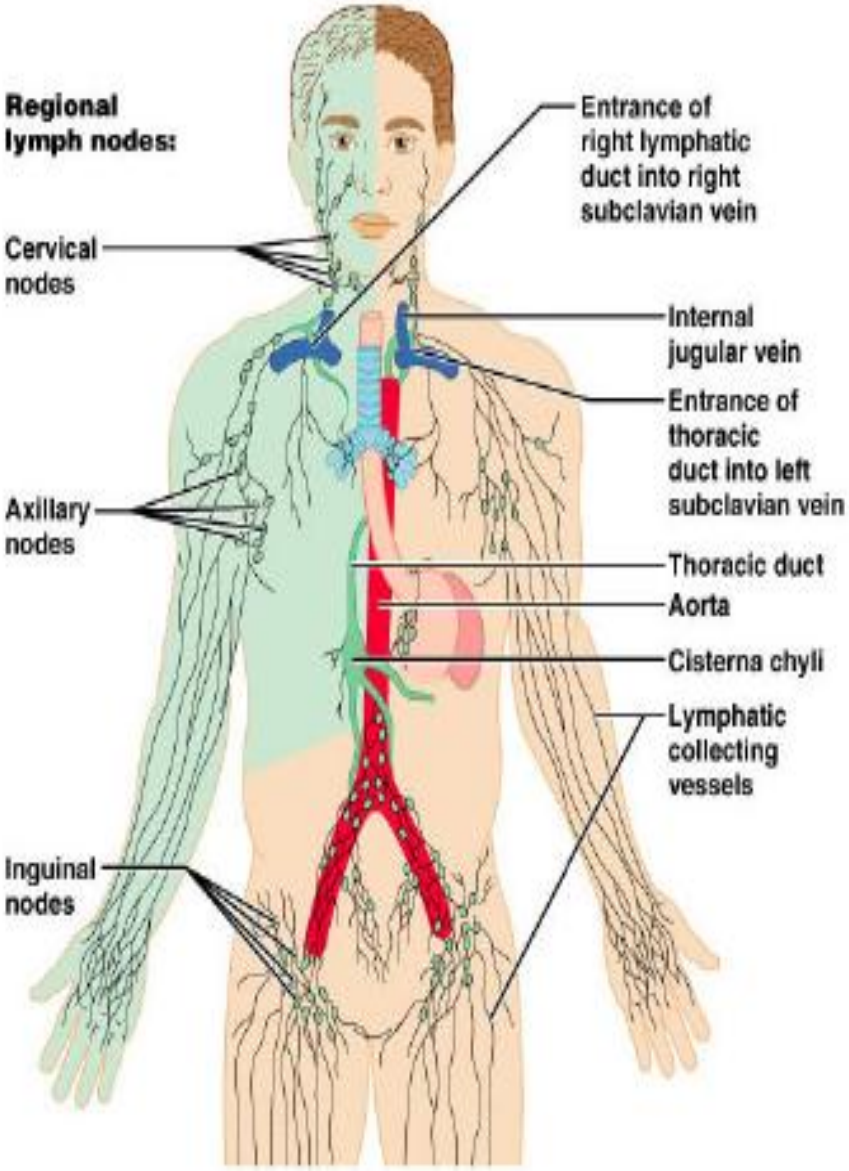

(a)

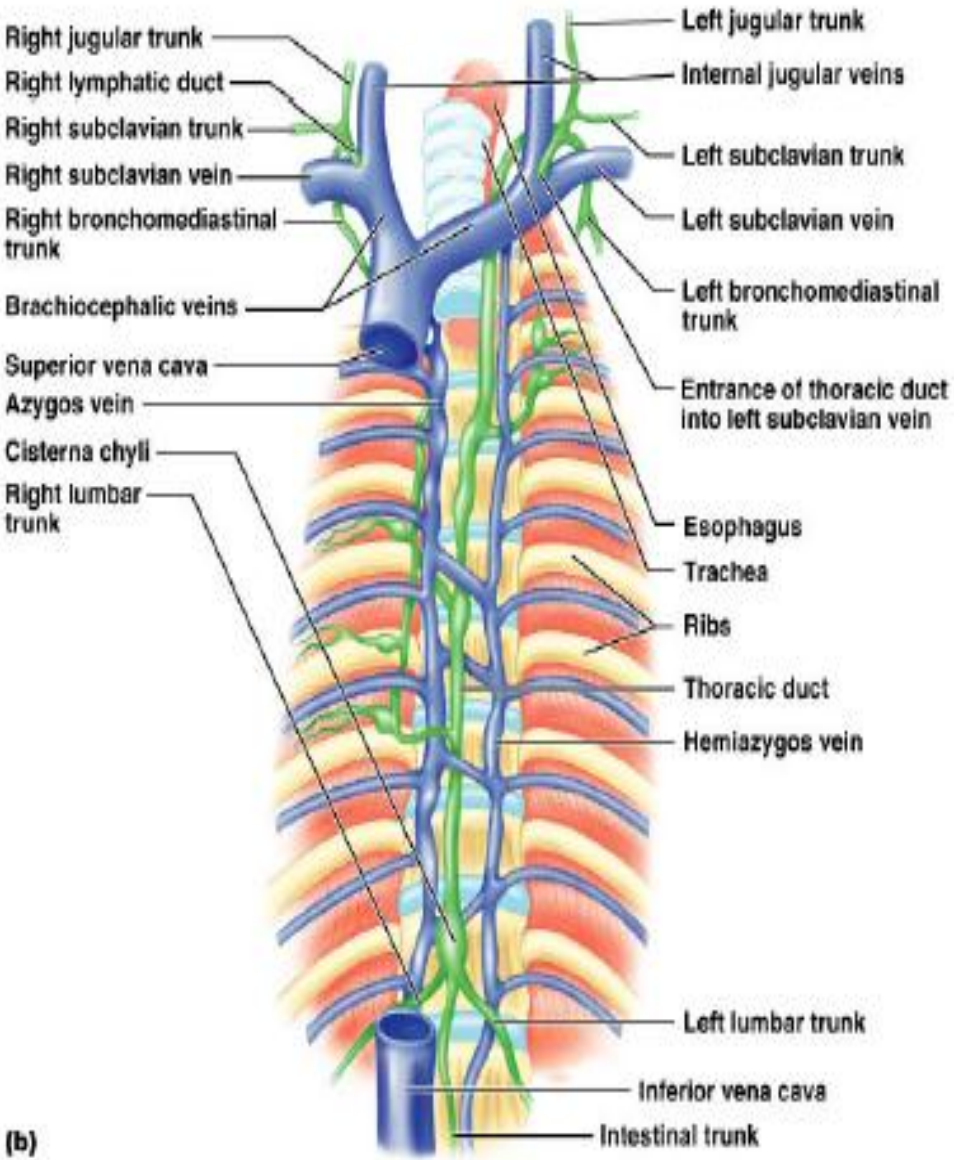

(b)

Lymphatic System: Overview

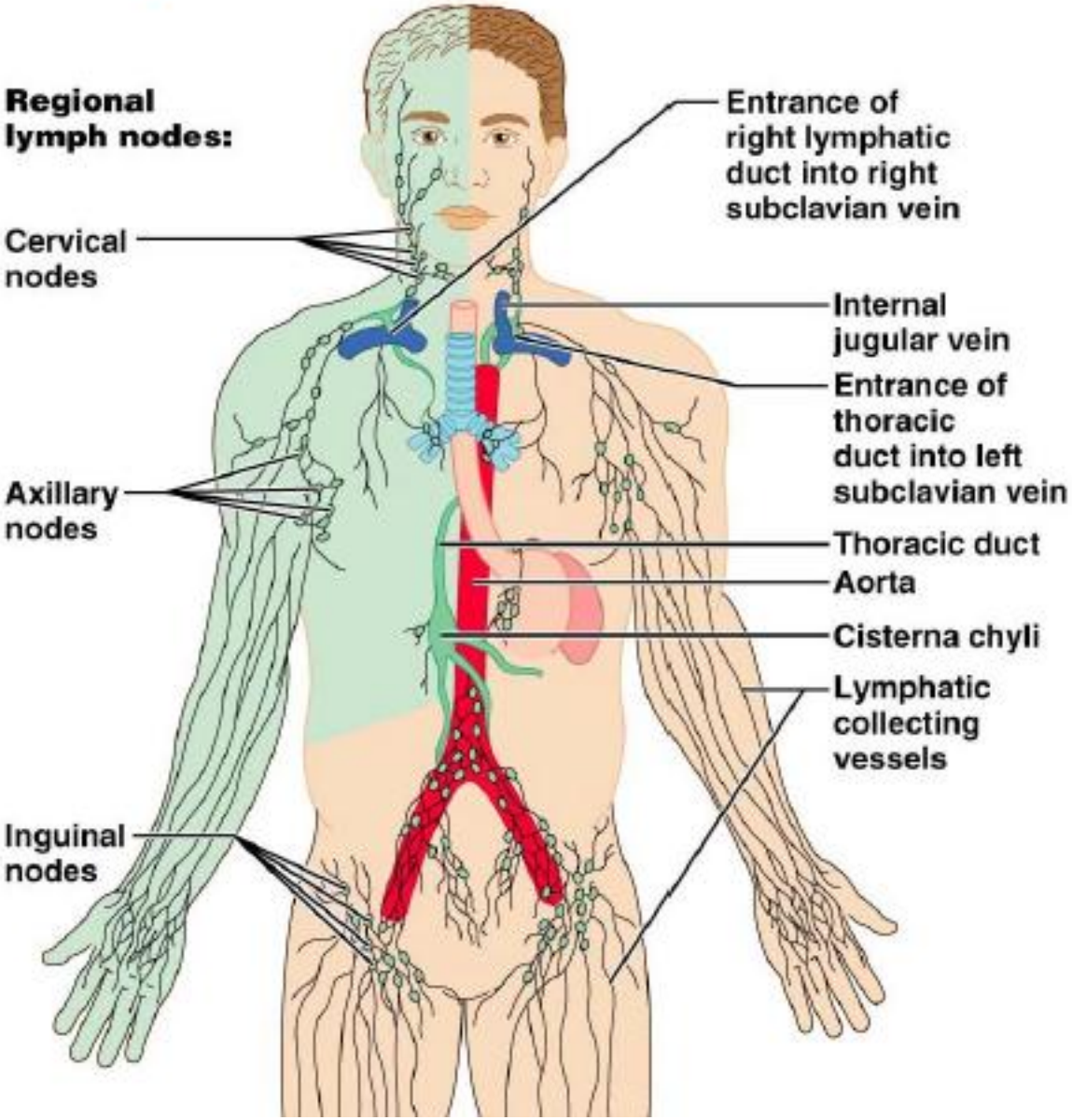

Lymphatic System: Overview

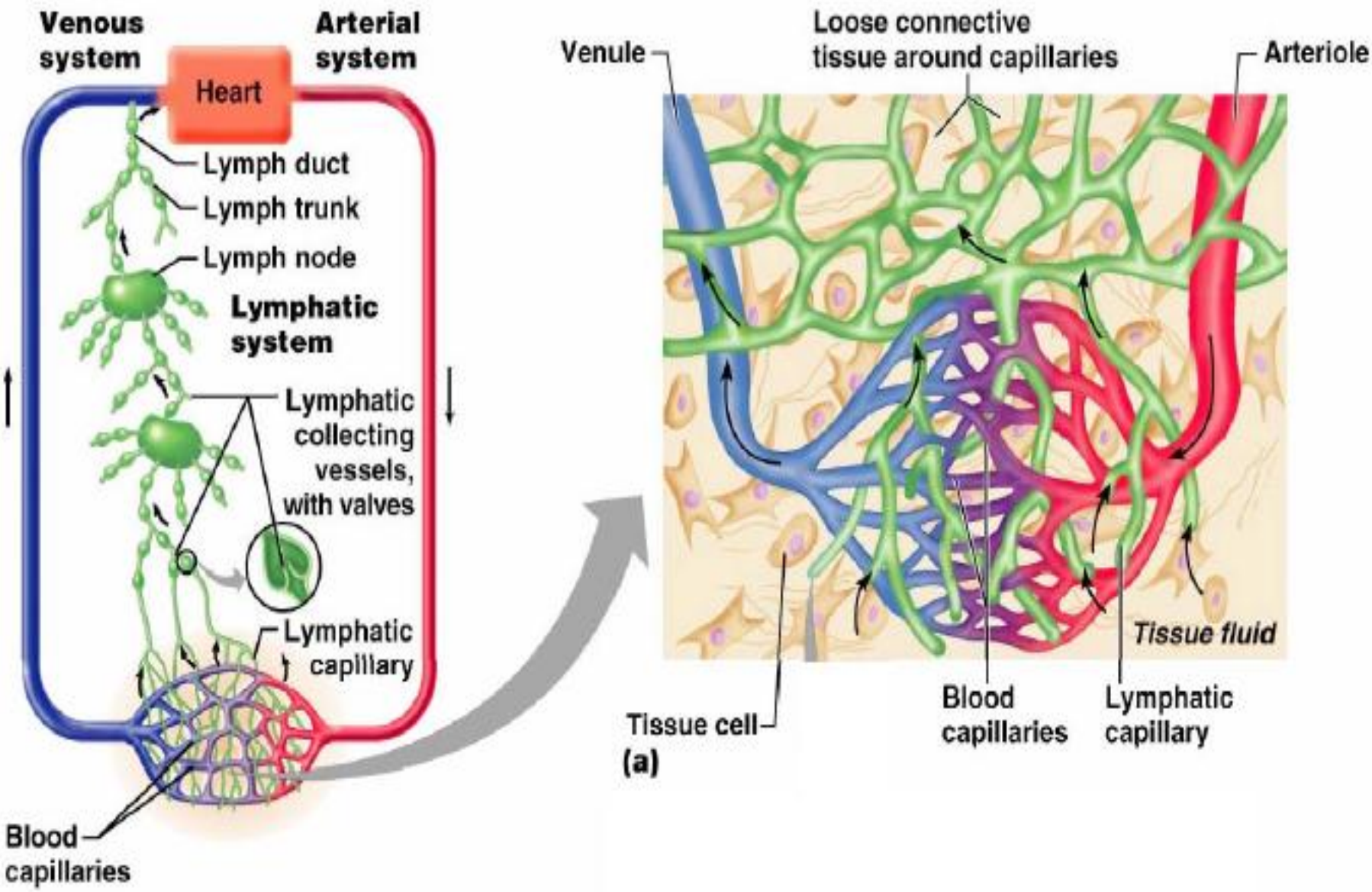

Lymphatic Vessels

- One-way system, lymph flows toward the heart
- Lymph vessels include:
  - Microscopic, permeable, blind-ended capillaries
  - Lymphatic collecting vessels
  - Trunks and ducts

Lymphatic Capillaries

- Similar to blood capillaries, with modifications:
  - Very permeable
  - Loosely joined endothelial minivalves
  - Withstand interstitial pressure and remain open
- The minivalves function as one-way gates that:
  - Allow interstitial fluid to enter lymph capillaries
  - Do not allow lymph to escape from the capillaries

Lymphatic Capillaries

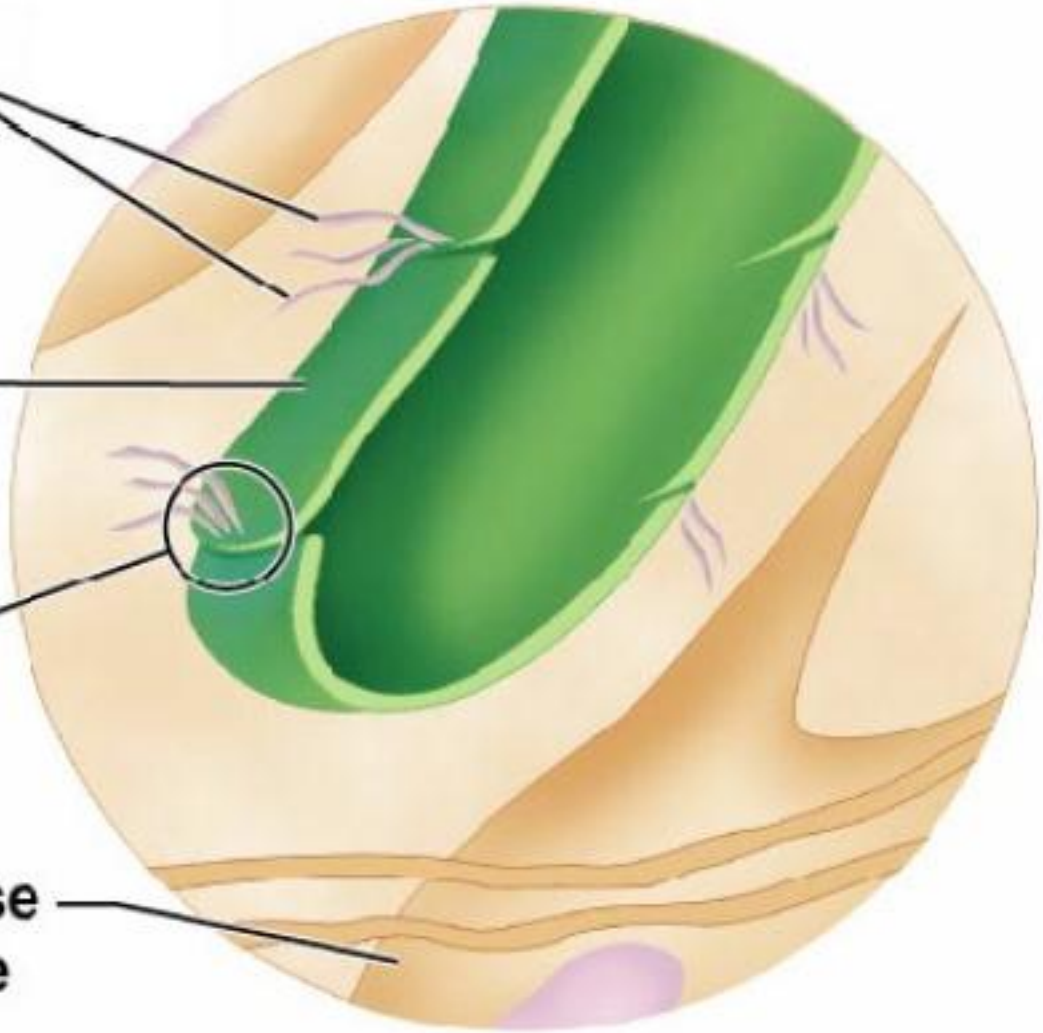

Lymphatic Capillaries

- During inflammation, lymph capillaries can absorb:
  - Cell debris
  - Pathogens
  - Cancer cells
- Cells in the lymph nodes cleanse and "examine" this debris
- Lacteals – specialized lymph capillaries present in intestinal mucosa
  - Absorb digested fat and deliver chyle to the blood

Lymphatic Collecting Vessels

- Have the same three tunics as veins
- Have thinner walls, with more internal valves
- Anastomose more frequently
- Collecting vessels in the skin travel with superficial veins
- Deep vessels travel with arteries
- Nutrients are supplied from branching vasa vasorum

Lymphatic Trunks

- Lymphatic trunks are formed by the union of the largest collecting ducts
- Major trunks include:
  - Paired lumbar, bronchomediastinal, subclavian, and jugular trunks
  - A single intestinal trunk

Lymphatic Trunks

- Lymph is delivered into one of two large trunks
  - Right lymphatic duct – drains the right upper arm and the right side of the head and thorax
  - Thoracic duct – arises from the cisterna chyli and drains the rest of the body

Lymphatic Trunks

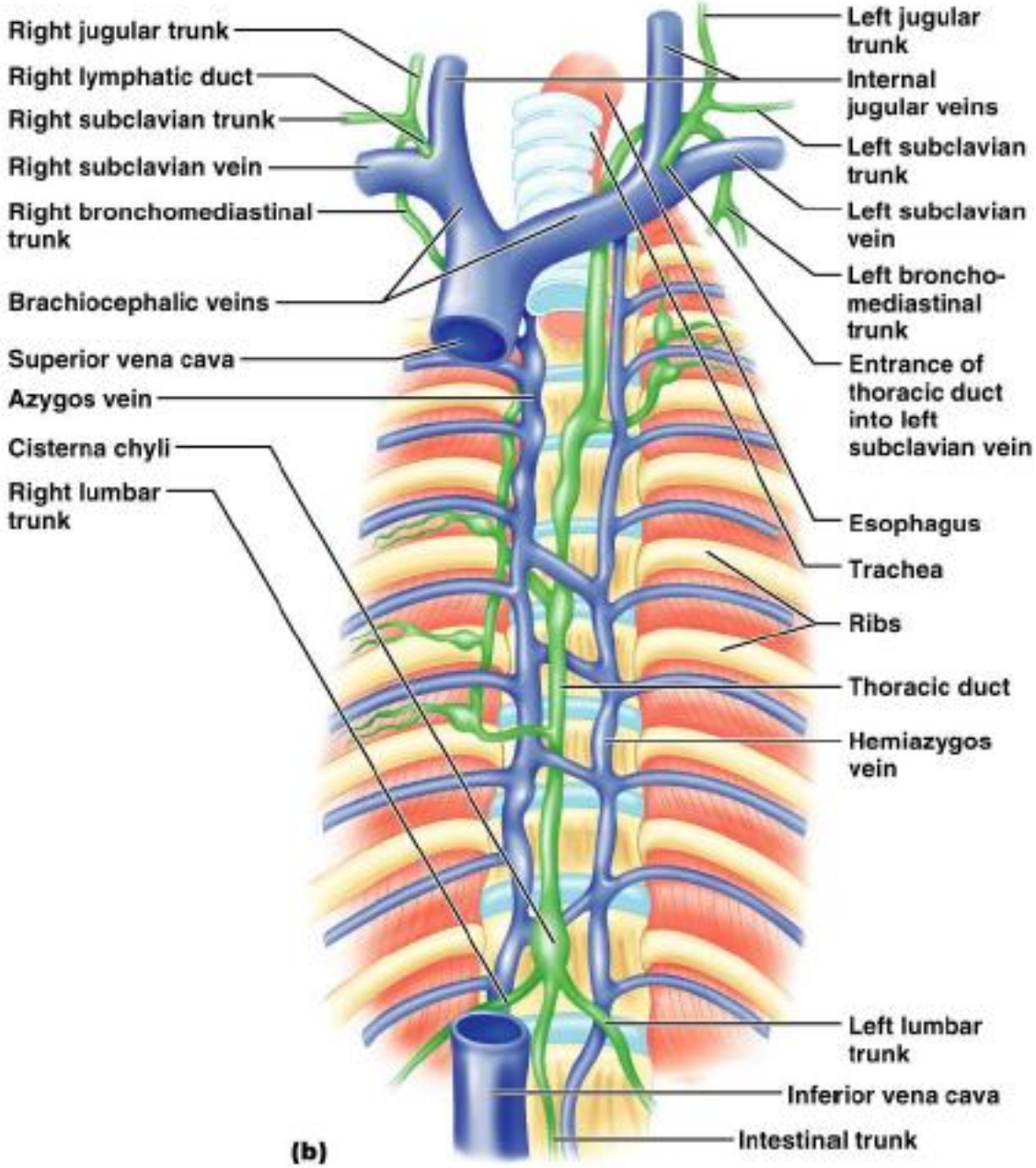

Lymph Transport

- The lymphatic system lacks a pumping organ
- Vessels are low-pressure conduits
- Uses the same methods as veins to propel lymph:
  - Pulsations of nearby arteries
  - Contractions of smooth muscle in the walls of the lymphatics

Lymphoid Cells

- Lymphocytes are the main cells involved in the immune response
- Two main varieties:
  - T cells
  - B cells

- **Lymphoid Cells**
  - **Lymphocytes**
    - **"Main Warriors"**
    - **Produced where?**
    - **Protect against antigens**
    - **Two major types**
      - **T Cells**
        - » **Orchestrate the immune response**
        - » **Some are direct killers that destroy foreign antigens**
      - **B Cells**
        - » **Produce plasma cells that in turn produce antibodies**

Lymphocytes

- T cells and B cells protect the body against antigens
- Antigen – anything the body perceives as foreign
  - Bacteria and their toxins; viruses
  - Mismatched RBCs or cancer cells

Lymphocytes

- T cells
  - Manage the immune response
  - Attack and destroy foreign cells
- B cells
  - Produce plasma cells, which secrete antibodies
  - Antibodies immobilize antigens

Other Lymphoid Cells

- Macrophages – phagocytize foreign substances and help activate T cells
- Dendritic cells – spiny-looking cells with functions similar to macrophages
- Reticular cells – fibroblast–like cells that produce a stroma, or network, that supports other cell types in lymphoid organs

- **Lymphoid Macrophages**
  - **Eat and destroy foreign antigens**
  - **Play a role in activating T Cells**
- **Dendritic Cells**
  - **Function like macrophages**
  - **Appear spiny**
  - **Found in lymphoid tissues**
- **Reticular Cells**
  - **Produce the fibrous stroma located in lymphoid organs**

Lymphoid Tissue

- Diffuse lymphatic tissue – scattered reticular tissue elements in every body organ
  - Larger collections appear in the lamina propria of mucous membranes and lymphoid organs
- Lymphatic follicles (nodules) – solid, spherical bodies consisting of tightly packed reticular elements and cells
  - Germinal center composed of dendritic and B cells
  - Found in isolation and as part of larger lymphoid organs

- **Lymphoid Tissues**
  - **Houses lymphocytes**
  - **Provides a "check point" for lymphocytes and macrophages to work**
  - **Composed of several types**
    - **Reticuar CT**
      - **Found in all lymphoid organs except the thymus gland**
        - » **Macrophages live on the fibers**
        - » **Lymphocytes live in the spaces between the fibers**

- **Diffuse Lymphatic Tissue**
  - **Scattered reticular tissue elements found in virtually all body organs**
  - **Larger numbers are found in mucous membranes**
- **Lymphoid Follicles (nodules)**
  - **Lack a capsule**
  - **Solid, spherical structures, with tightly packed reticular elements**
  - **Often have light centers (germinal centers) that contain dendritic cells and B Cells**
  - **Good example, Peyer's patches in the intestines and appendix**

Lymph Nodes

- Principal lymphoid organs of the body
- Embedded in connective tissue and clustered along lymphatic vessels
- Aggregations of these nodes occur near the body surface in inguinal, axillary, and cervical regions of the body

- **Lymph Nodes**

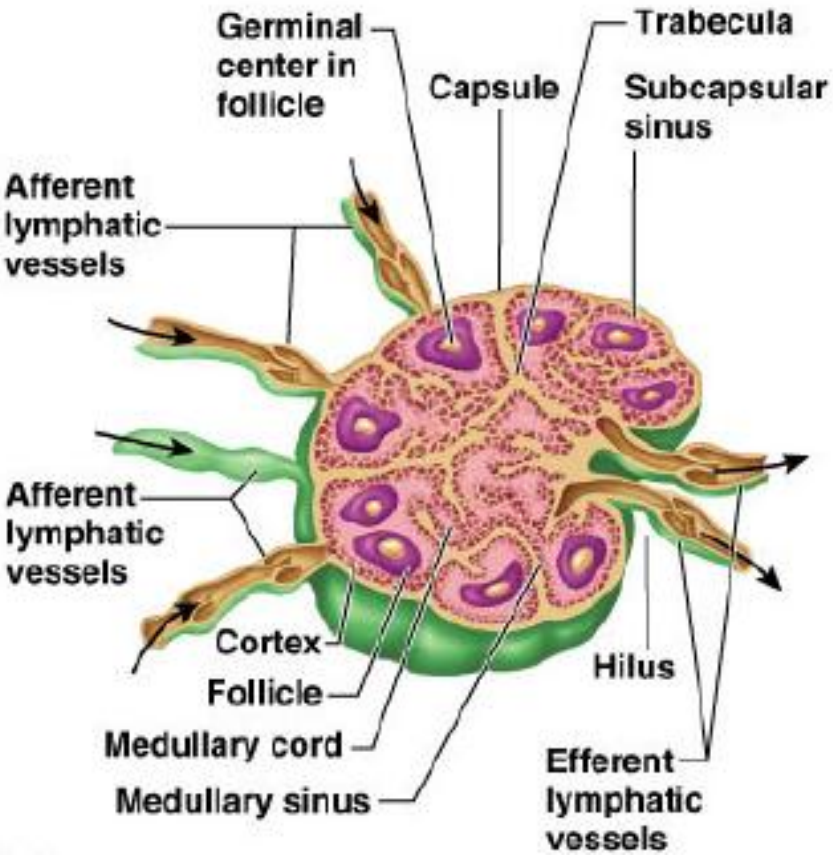

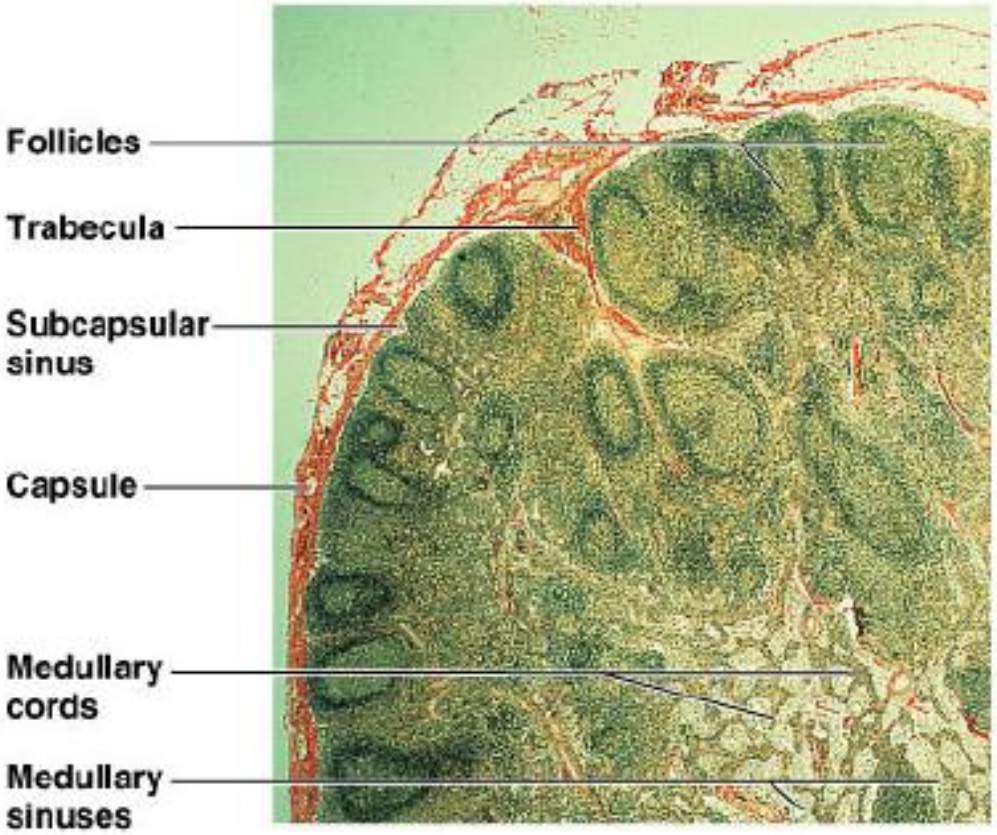

Lymph Nodes

- Two basic functions:
  - Filtration – macrophages destroy microorganisms and debris
  - Immune system activation – monitor for antigens and mount an attack against them

Structure of a Lymph Node

- Nodes are bean shaped and surrounded by a fibrous capsule
- Trabeculae extended inward from the capsule and divide the node into compartments
- Nodes have two histologically distinct regions: a cortex and a medulla

Structure of a Lymph Node

- Cortex contains follicles with germinal centers, heavy with dividing B cells
- Dendritic cells nearly encapsulate the follicles
- Deep cortex houses T cells in transit
- T cells circulate continuously among the blood, lymph nodes, and lymphatic stream

Structure of a Lymph Node

- Medullary cords extend from the cortex and contain B cells, T cells, and plasma cells
- Throughout the node are lymph sinuses crisscrossed by reticular fibers
- Macrophages reside on these fibers and phagocytize foreign matter

Circulation in the Lymph Nodes

- Lymph enters via afferent lymphatic vessels
- It then enters a large subcapsular sinus and travels into smaller sinuses
- It meanders through these sinuses and exits the node at the hilus via efferent vessels
- Because there are fewer efferent vessels, lymph stagnates somewhat in the node
- This allows lymphocytes and macrophages time to carry out protective functions

Lymphoid Organs

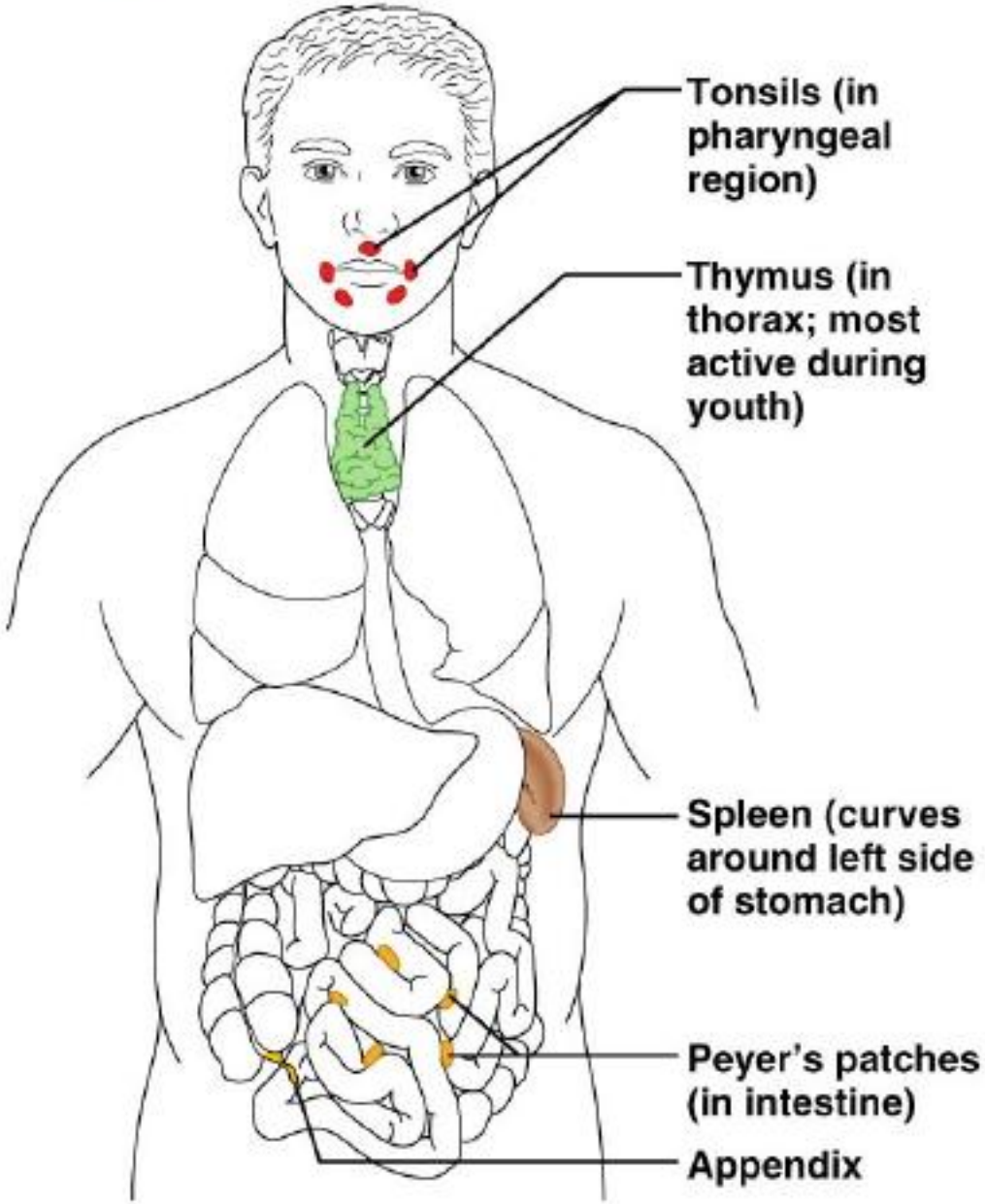

Other Lymphoid Organs

- The spleen, thymus gland, and tonsils
- Peyer's patches and bits of lymphatic tissue scattered in connective tissue
- All are composed of reticular connective tissue
- All help protect the body
- Only lymph nodes filter lymph

- **Spleen**
  - **Site for lymphocytes to proliferate and do their job of surveillance**
  - **Cleans the blood (much like lymph nodes clean lymph) - removes old RBC's and platelets**
  - **Aids in recycling RBC components**
  - **Site of erytropoiesis in the fetus**
  - **Stores blood and platelets**

Spleen

- Largest lymphoid organ, located on the left side of the abdominal cavity beneath the diaphragm
- It is served by the splenic artery and vein, which enter and exit at the hilus
- Functions:
  - Site of lymphocyte proliferation
  - Immune surveillance and response
  - Cleanses the blood

Additional Spleen Functions

- Stores breakdown products of RBCs for later reuse
  - Spleen macrophages salvage and store iron for later use by bone marrow
- Site of fetal erythrocyte production (normally ceases after birth)
- Stores blood platelets

Structure of the Spleen

- Surrounded by a fibrous capsule, it has trabeculae that extend inward and contains lymphocytes, macrophages, and huge numbers of erythrocytes
- Two distinct areas:
  - White pulp – containing mostly lymphocytes suspended on reticular fibers and involved in immune functions
  - Red pulp – remaining splenic tissue concerned with disposing of worn-out RBCs and bloodborne pathogens

Structure of the Spleen

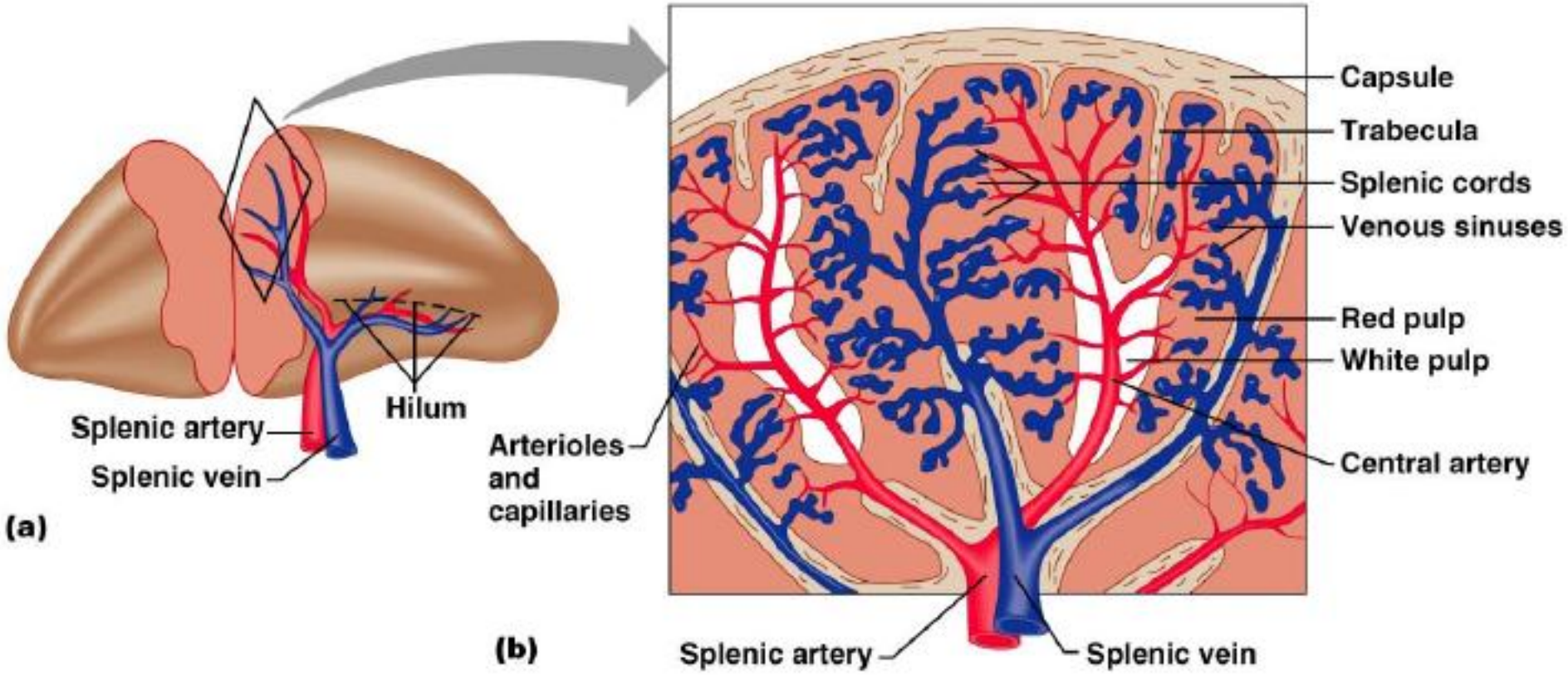

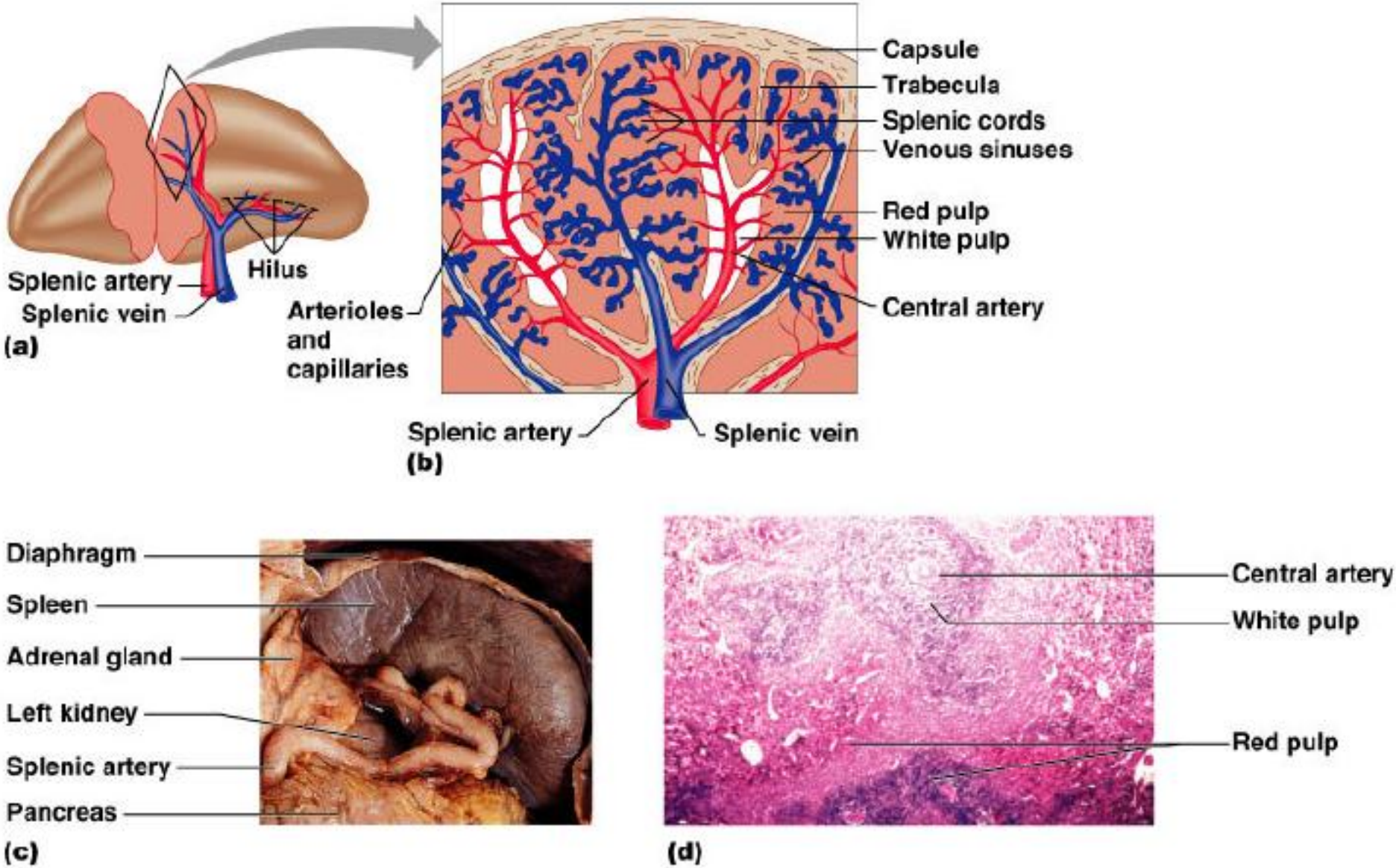

- **Thymus Gland – important in early life**
  - **Secretes two hormones that play an important role in T lymphocytes becoming immunocompetent**
- **Tonsils – named according to location**
  - **Palatine – paired, on either side of the soft palate**
  - **Lingual – paired at the base of the tongue**
  - **Pharyngeal – located in the posterior portion of the nasopharynx**

Thymus

- A bilobed organ that secretes hormones (thymosin and thymopoietin) that cause T lymphocytes to become immunocompetent
- Size of the thymus varies with age:
  - In infants, it is found in the inferior neck and extends into the mediastinum where it partially overlies the heart
  - It increases in size and is most active during childhood
  - It stops growing during adolescence and then gradually atrophies

Internal Anatomy of the Thymus

- Thymic lobes contain an outer cortex and inner medulla
- Cortex contains densely packed lymphocytes and scattered macrophages
- Medulla contains fewer lymphocytes and thymic (Hassall's) corpuscles

Thymus

- The thymus differs from other lymphoid organs in important ways
  - It functions strictly in T lymphocyte maturation
  - It does not directly fight antigens
- The stroma of the thymus consists of star-shaped epithelial cells (not reticular fibers)
- These thymocytes secrete the hormones that stimulate lymphocytes to become immunocompetent

Tonsils

- Simplest lymphoid organs; form a ring of lymphatic tissue around the pharynx
- Location:
  - Palatine tonsils – either side of the posterior end of the oral cavity
  - Lingual tonsils – lie at the base of the tongue
  - Pharyngeal tonsil – posterior wall of the nasopharynx
  - Tubal tonsils – surround the openings of the auditory tubes into the pharynx

Tonsils

- Lymphoid tissue of tonsils contains follicles with germinal centers
- Tonsil masses are not fully encapsulated
- Epithelial tissue overlying tonsil masses invaginates, forming blind-ended crypts
- Crypts trap and destroy bacteria and particulate matter

- **Aggregates of Lymphoid Follicles**
  - **Protect both the respiratory and digestive tracts**
  - **Part of a collection of lymphoid tissues called mucosa-associated lymphatic tissue; MALT**

Aggregates of Lymphoid Follicles

- Peyer's patches – isolated clusters of lymphoid tissue, similar to tonsils
  - Found in the wall of the distal portion of the small intestine
  - Similar structures are found in the appendix
- Peyer's patches and the appendix:
  - Destroy bacteria, preventing them from breaching the intestinal wall
  - Generate "memory" lymphocytes for long-term immunity

MALT

- MALT – mucosa-associated lymphatic tissue:
  - Peyer's patches, tonsils, and the appendix (digestive tract)
  - Lymphoid nodules in the walls of the bronchi (respiratory tract)
- MALT protects the digestive and respiratory systems from foreign matter

Developmental Aspects

- Beginnings of the lymphatic vessels and main clusters of lymph nodes are apparent by the fifth week of embryonic development
  - These arise from the budding of lymph sacs from developing veins
- Lymphatic organs (except the thymus) arise from mesoderm

Developmental Aspects

- The thymus (endodermal origin) forms as an outgrowth of the pharynx
- Except for the spleen and tonsils, lymphoid organs are poorly developed at birth

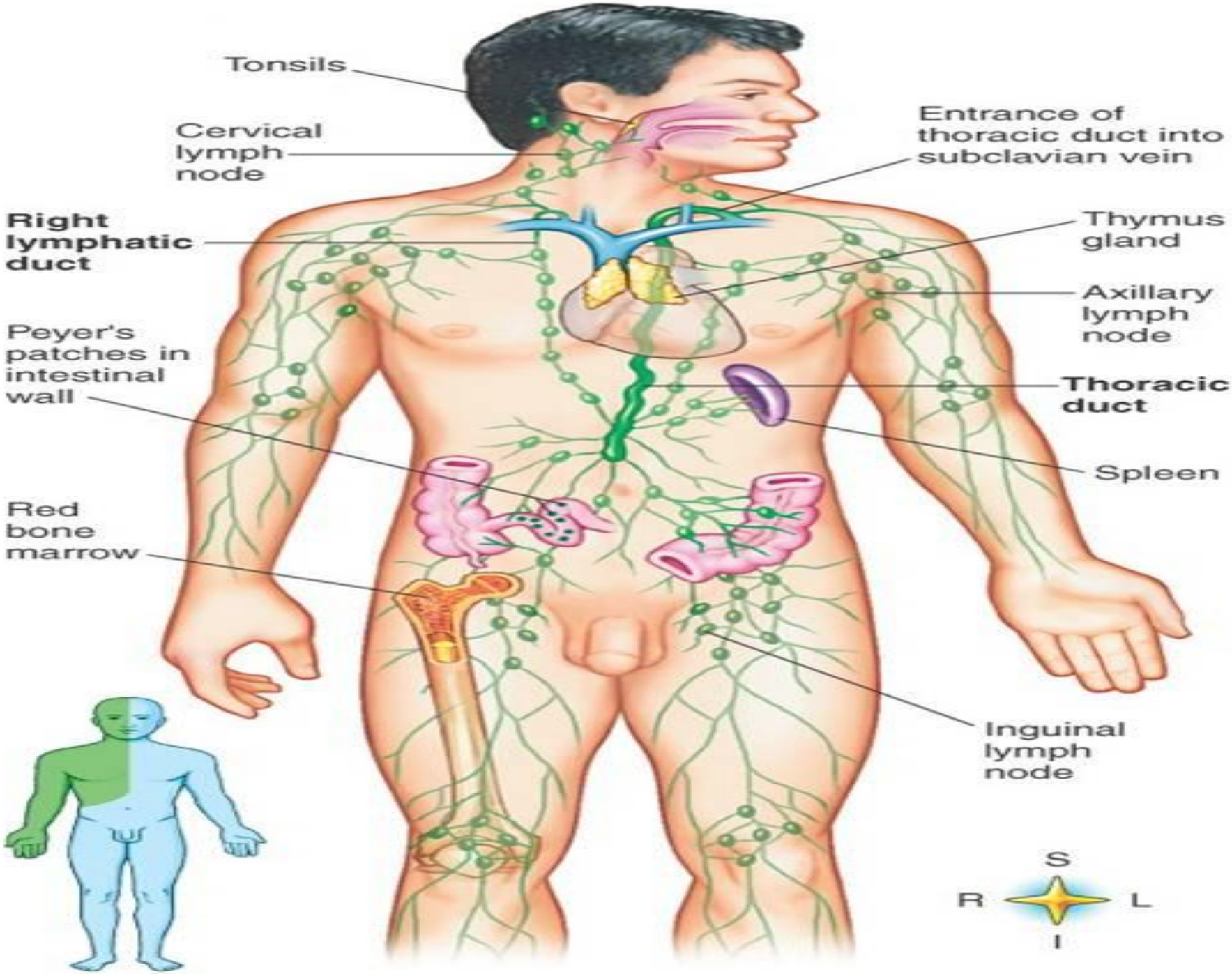
Tonsils
Cervical lymph node
Right lymphatic duct
Peyer's patches in intestinal wall
Red bone marrow
Entrance of thoracic duct into subclavian vein
Thymus gland
Axillary lymph node
Thoracic duct
Spleen
Inguinal lymph node
S
R
L
I

Organs of the Immune System

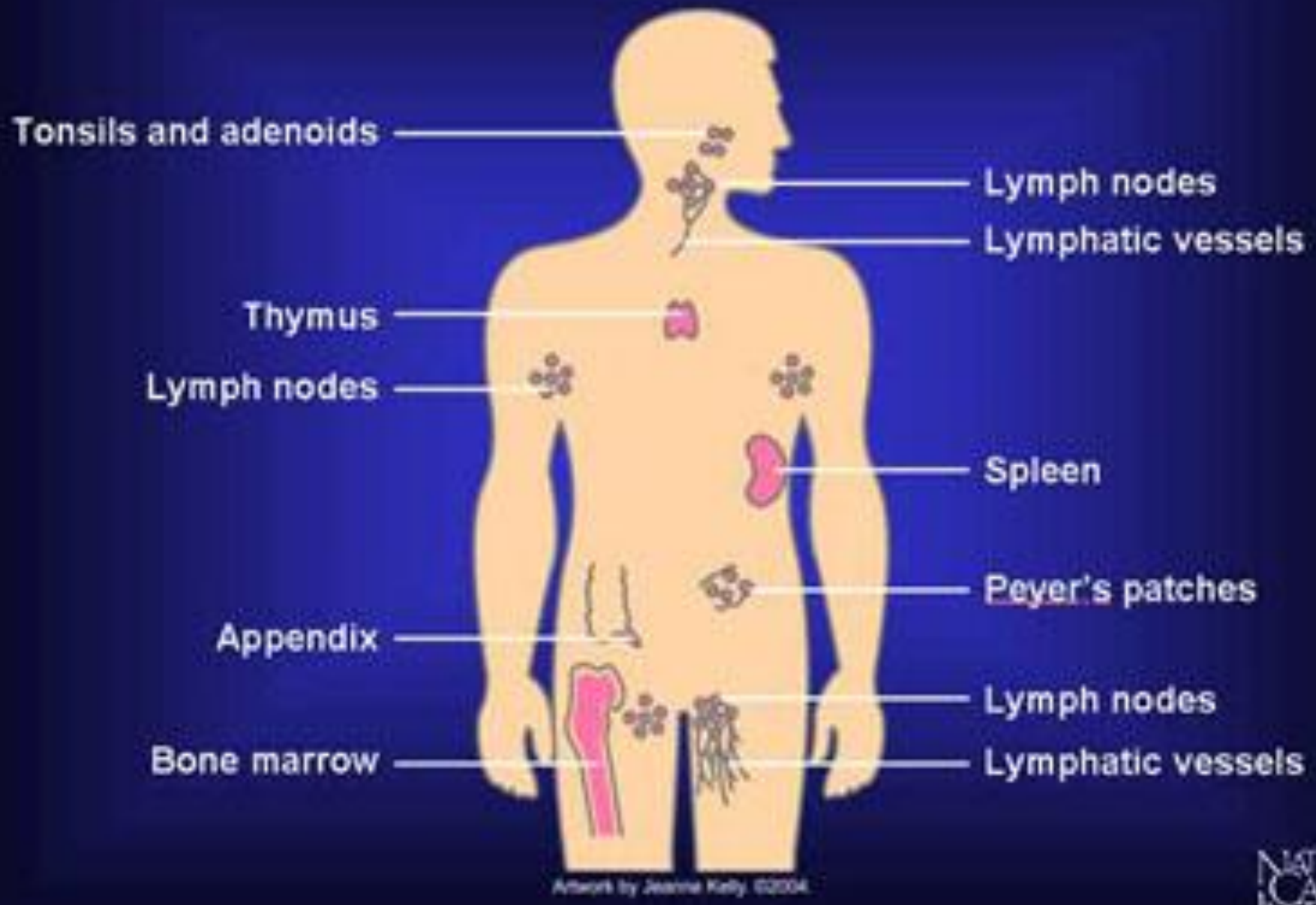

NATIONAL CANCER INSTITUTE

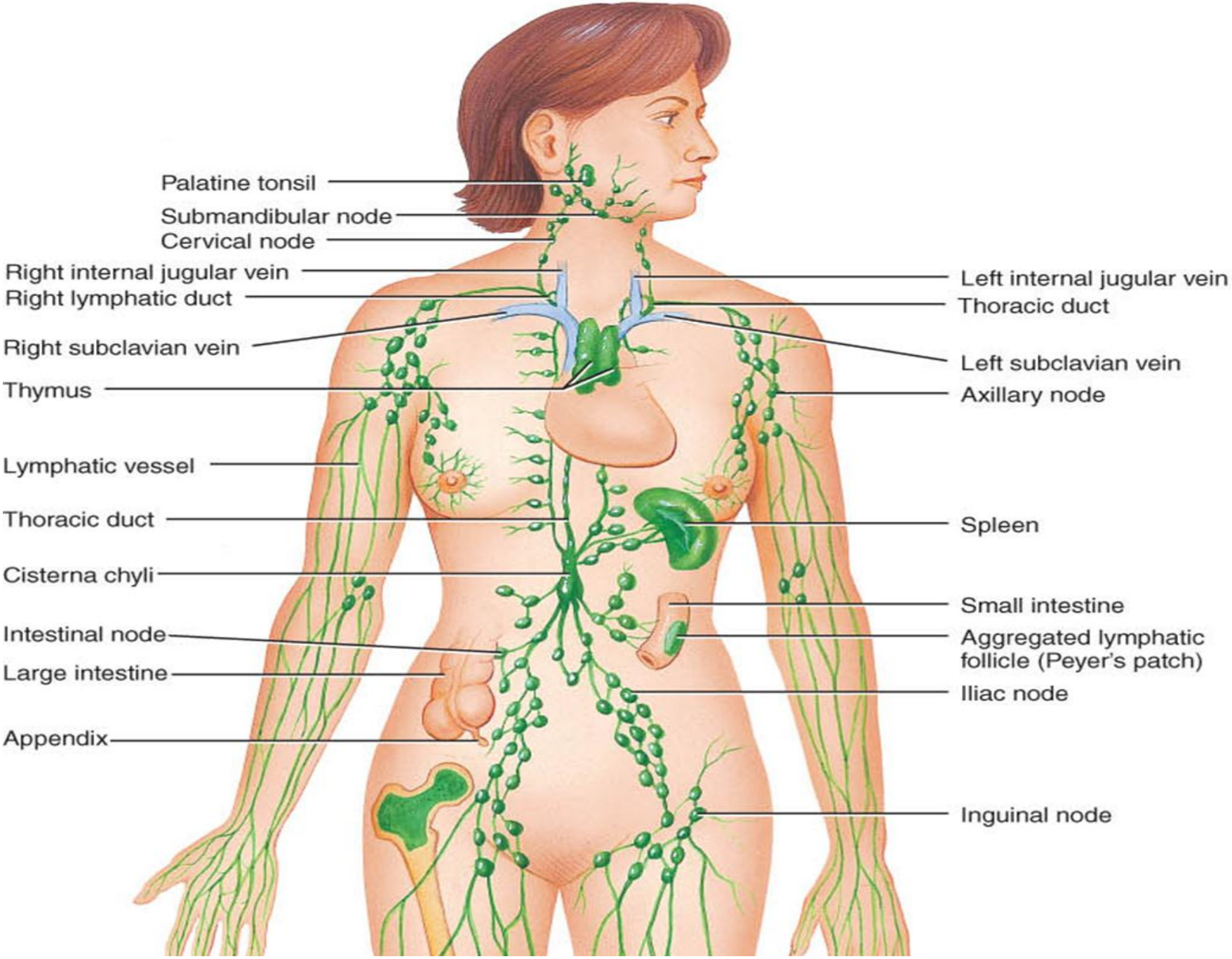

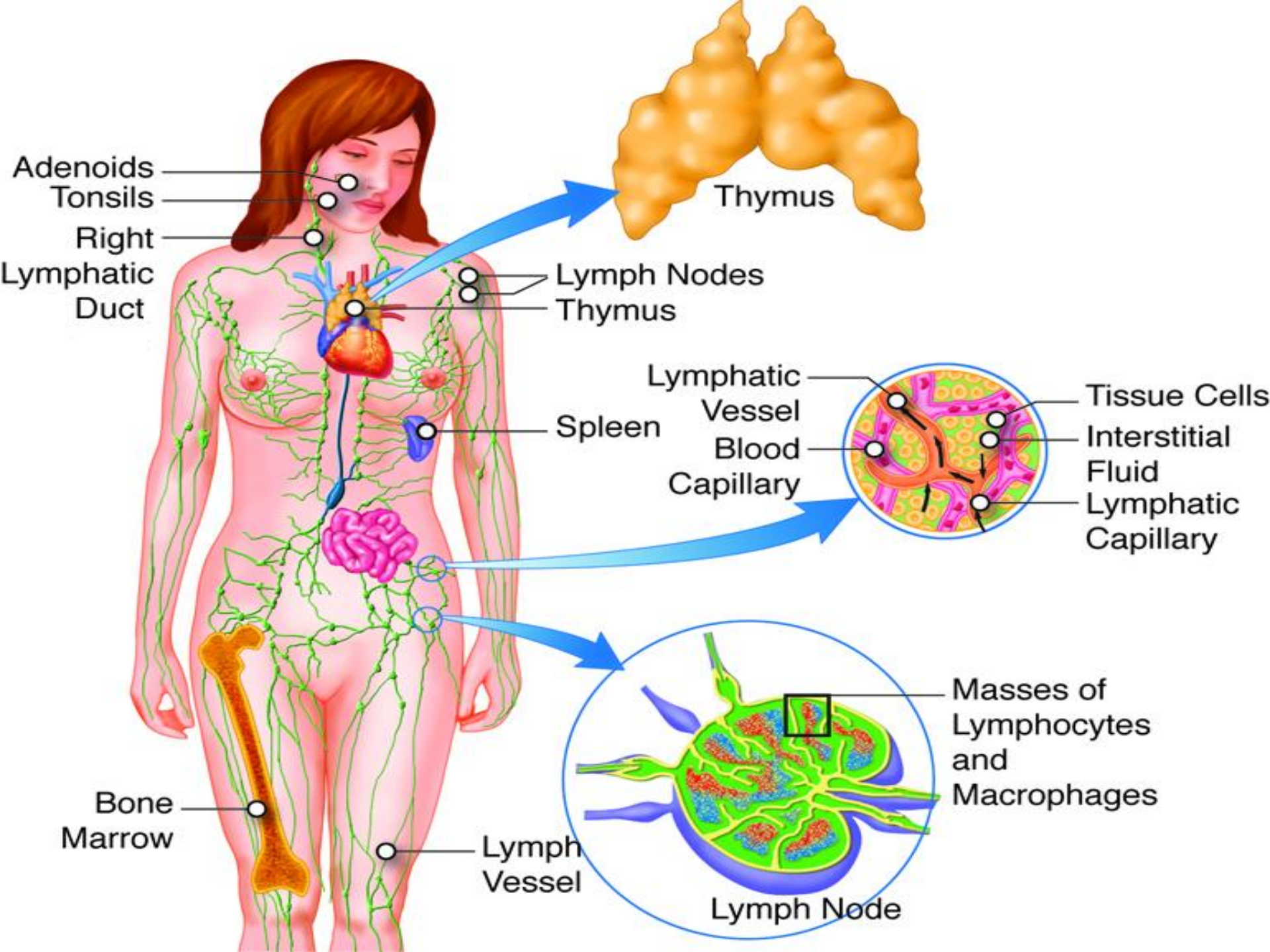
Adenoids
Tonsils
Right Lymphatic Duct
Lymph Nodes
Thymus
Thymus
Spleen
Lymphatic Vessel
Blood Capillary
Tissue Cells
Interstitial Fluid
Lymphatic Capillary
Masses of Lymphocytes and Macrophages
Lymph Node
Bone Marrow
Lymph Vessel