The Integumentary System

The skin and its accessory structures

Functions of the Integumentary System

- Guard the body's physical and biochemical integrity
- Maintain a constant body temperature
- Provide sensory information about the surrounding environment.

The Skin

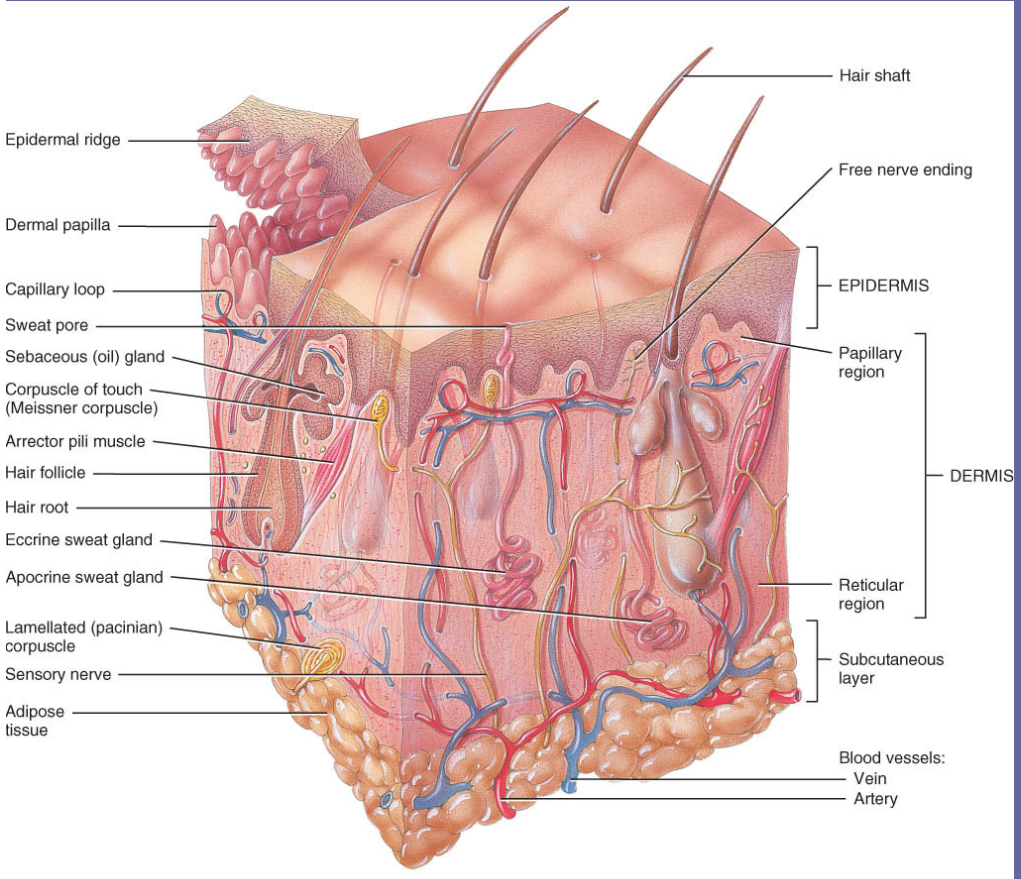

(a) Sectional view of skin and subcutaneous layer

- A large organ composed of all 4 tissue types
- 22 square feet
- 1-2 mm thick
- Weight 10 lbs.

STRUCTURE OF THE SKIN

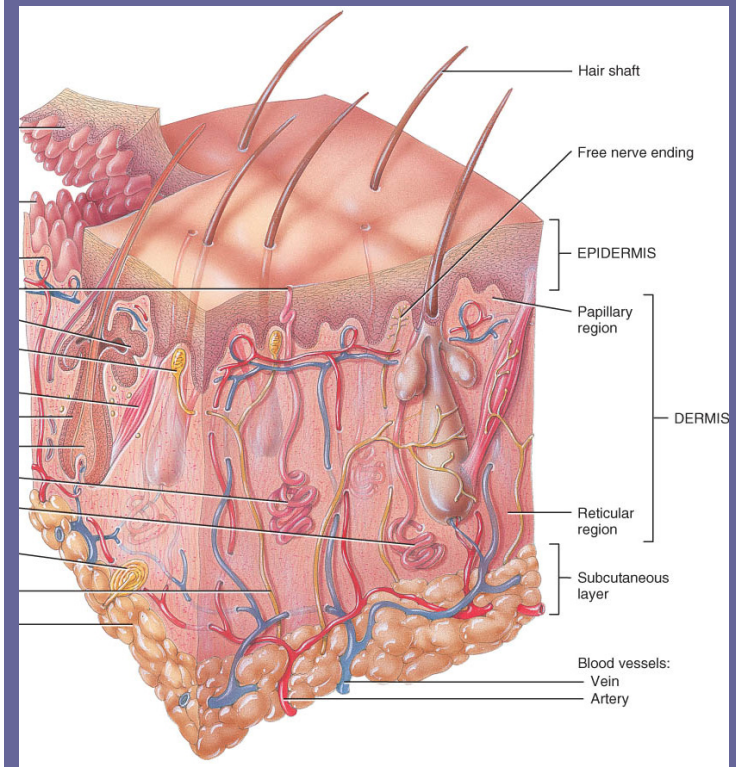

(a) Sectional view of skin and subcutaneous layer

- *epidermis*
  - The superficial portion of the skin
  - Composed of epithelial tissue.
- *dermis*
  - The deeper layer of the skin
  - Primarily composed of connective tissue.
- Deep to the dermis is the *subcutaneous layer* or hypodermis. (*not* a part of the skin)
  - It *consists* of areolar and adipose tissue.
  - fat storage, an area for blood vessel passage, and an area of pressure-sensing nerve endings.

Overview of Epidermis

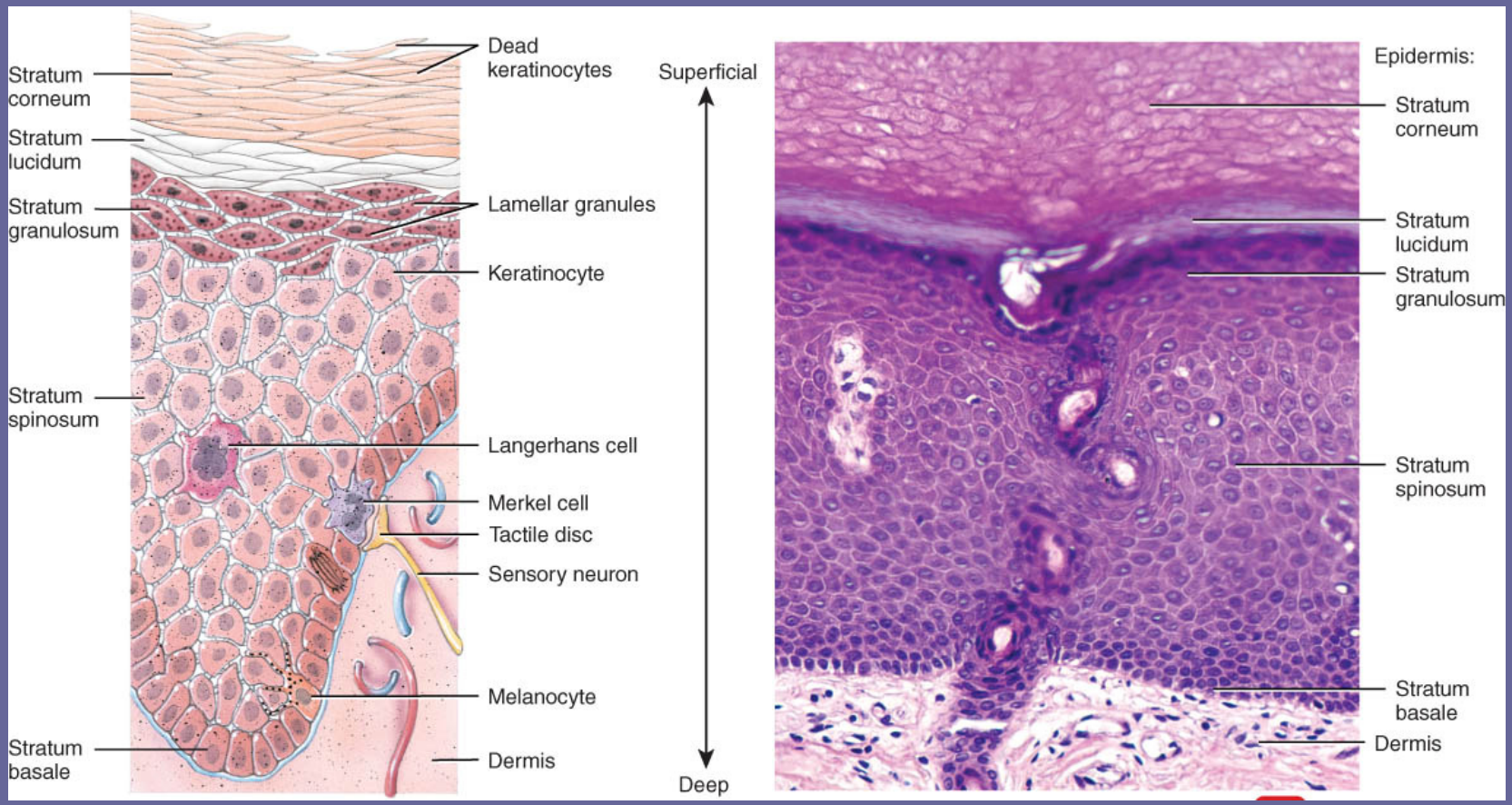

- Stratified squamous epithelium
  - avascular (contains no blood vessels)
  - 4 types of cells
  - 5 distinct strata (layers) of cells

Four Principle Cells of the Epidermis

- *keratinocytes*
  - produce the protein keratin, which helps protect the skin and underlying tissue from heat, microbes, and chemicals, and lamellar granules, which release a waterproof sealant
- *melanocytes*
  - produce the pigment melanin which contributes to skin color and absorbs damaging ultraviolet (UV) light
- *Langerhans cells*
  - derived from bone marrow
  - participate in immune response
- *Merkel cells*
  - contact a sensory structure called a tactile (Merkel) disc and function in the sensation of touch

Layers of the Epidermis

- From deepest to most superficial the layers of the epidermis are
  - stratum basale (stratum germinativum)
  - stratum spinosum
  - stratum granulosum
  - stratum lucidum (only in palms and soles)
  - stratum corneum

Layers (Strata) of the Epidermis

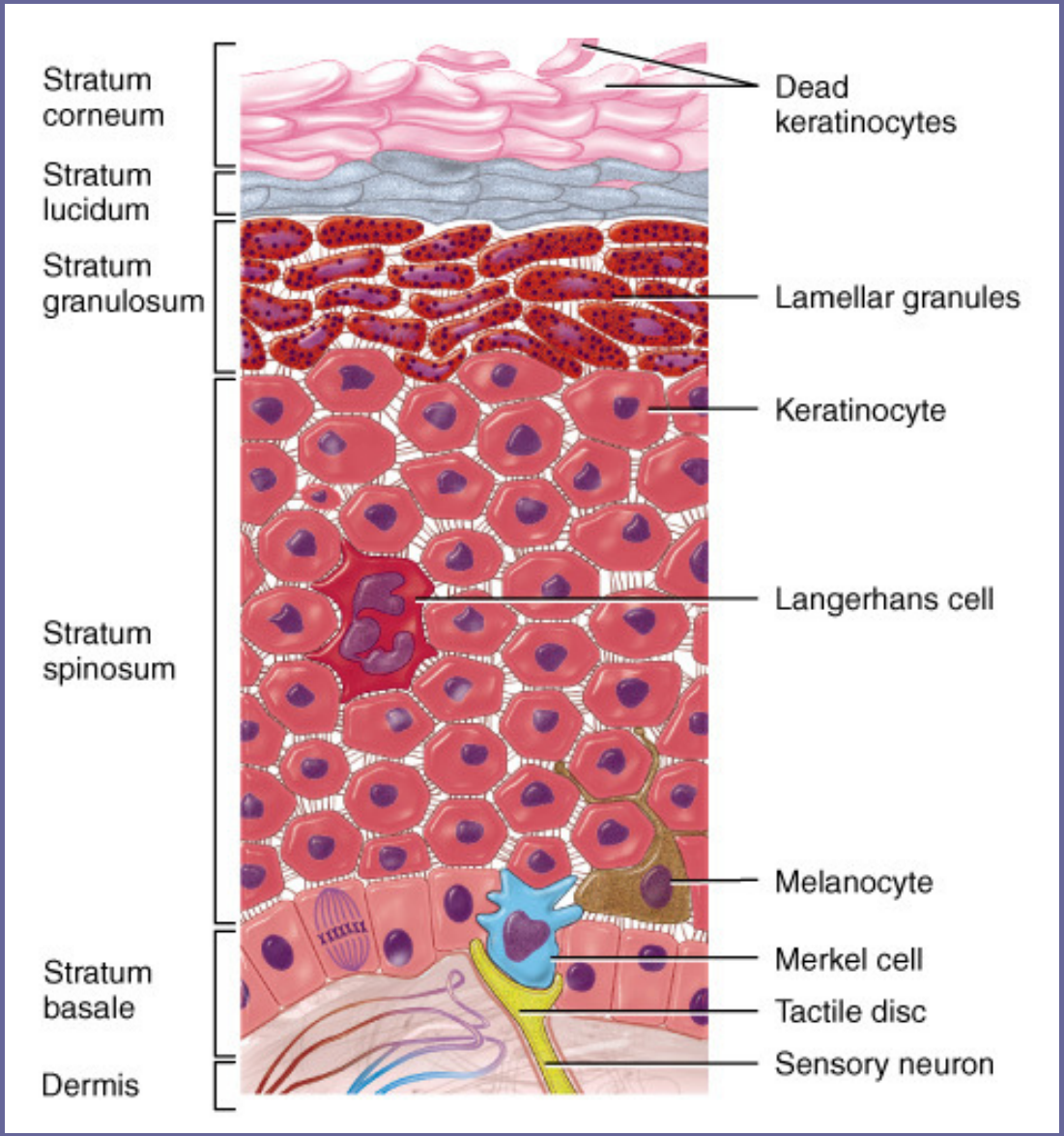

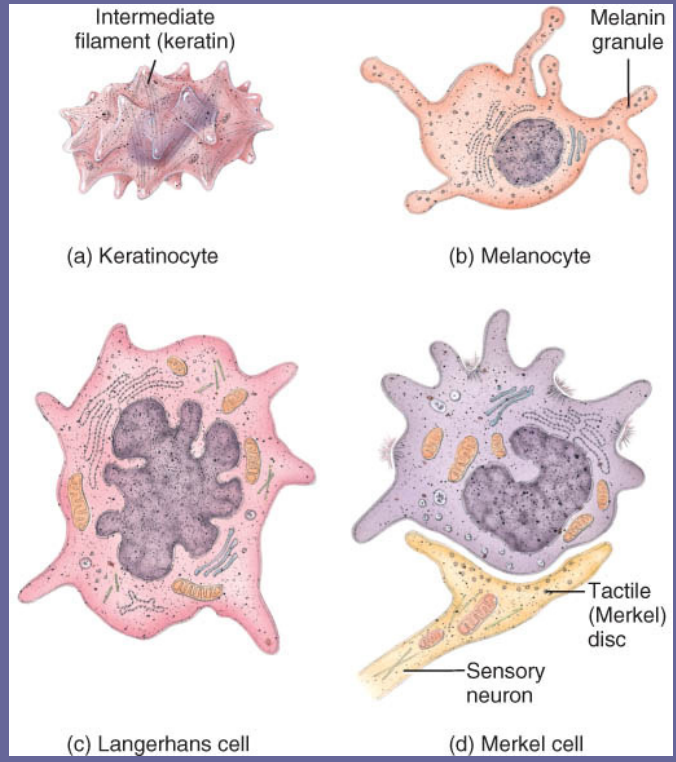

Stratum Basale (stratum germinativum)

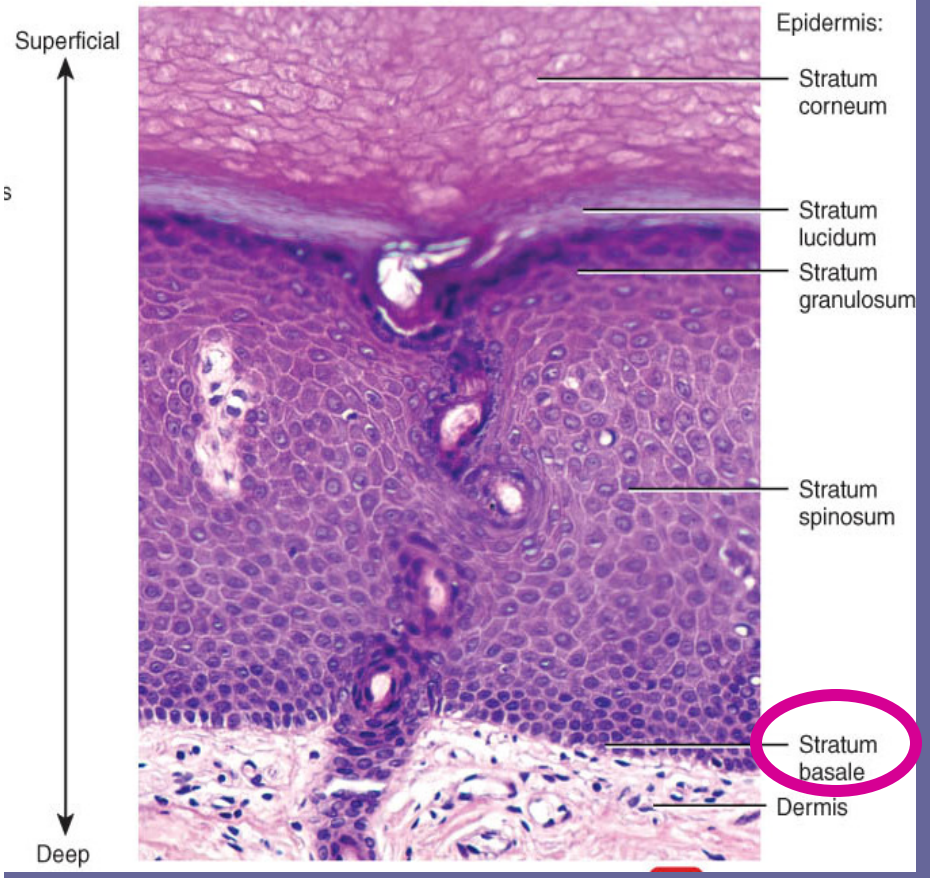

- Deepest single layer of epidermis
  - merkel cells, melanocytes, keratinocytes & stem cells that divide repeatedly
  - keratinocytes have a cytoskeleton of tonofilaments
  - Cells attached to each other & to basement membrane by desmosomes & hemi-desmosomes
- When the germinal portion of the epidermis is destroyed, new skin cannot regenerate with a *skin graft*.

Stratum Spinosum

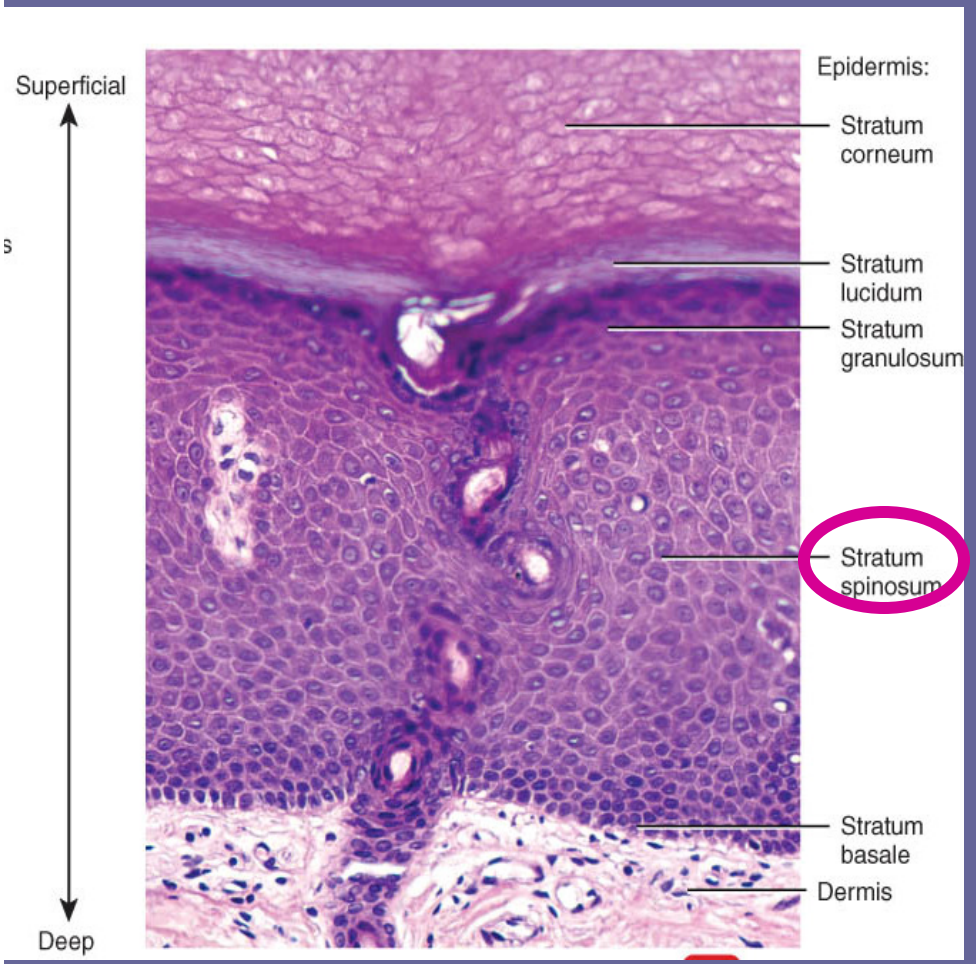

- provides strength and flexibility to the skin
  - 8 to 10 cell layers are held together by desmosomes.

Stratum Granulosum

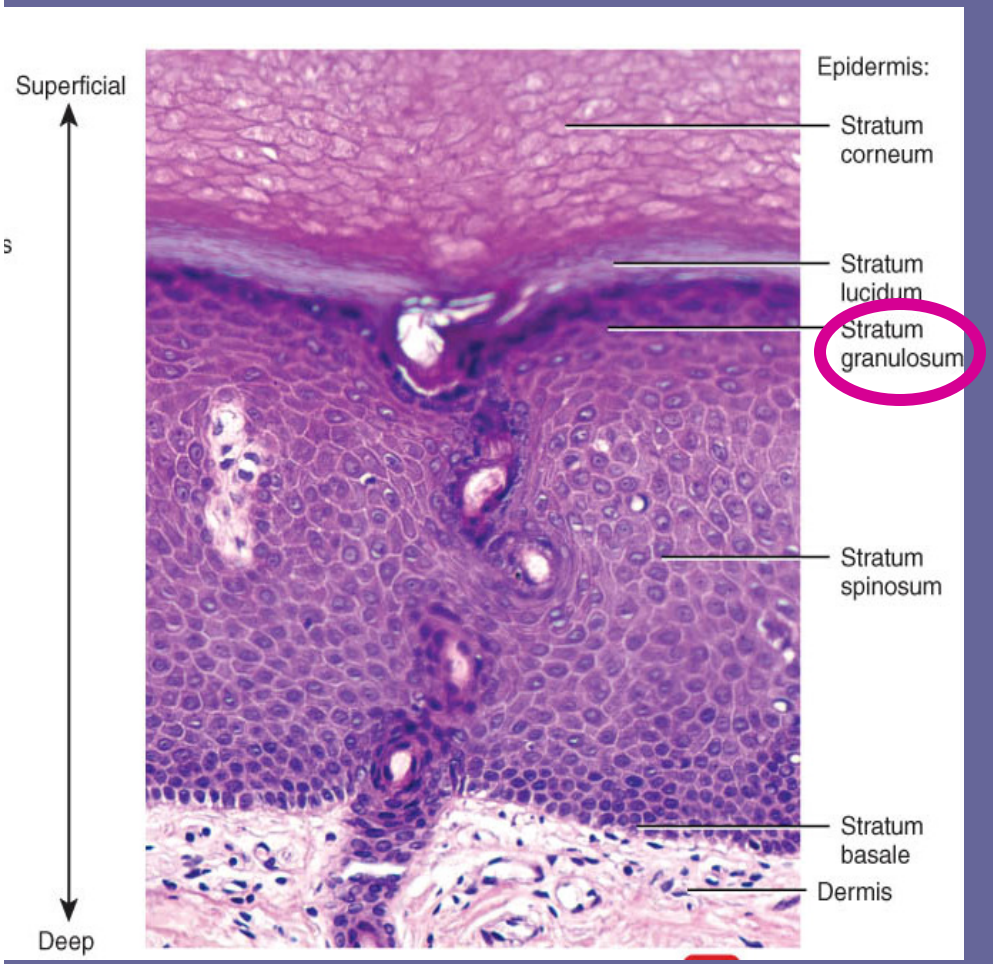

- transition between the deeper, metabolically active strata and the dead cells of the more superficial strata
- 3-5 layers of flat dying cells that show nuclear degeneration
  - example of apoptosis
- Contain lamellar granules that release lipid that repels water
- Contain dark-staining keratohyalin granules
  - keratohyalin converts tonofilaments into keratin

Stratum Lucidum

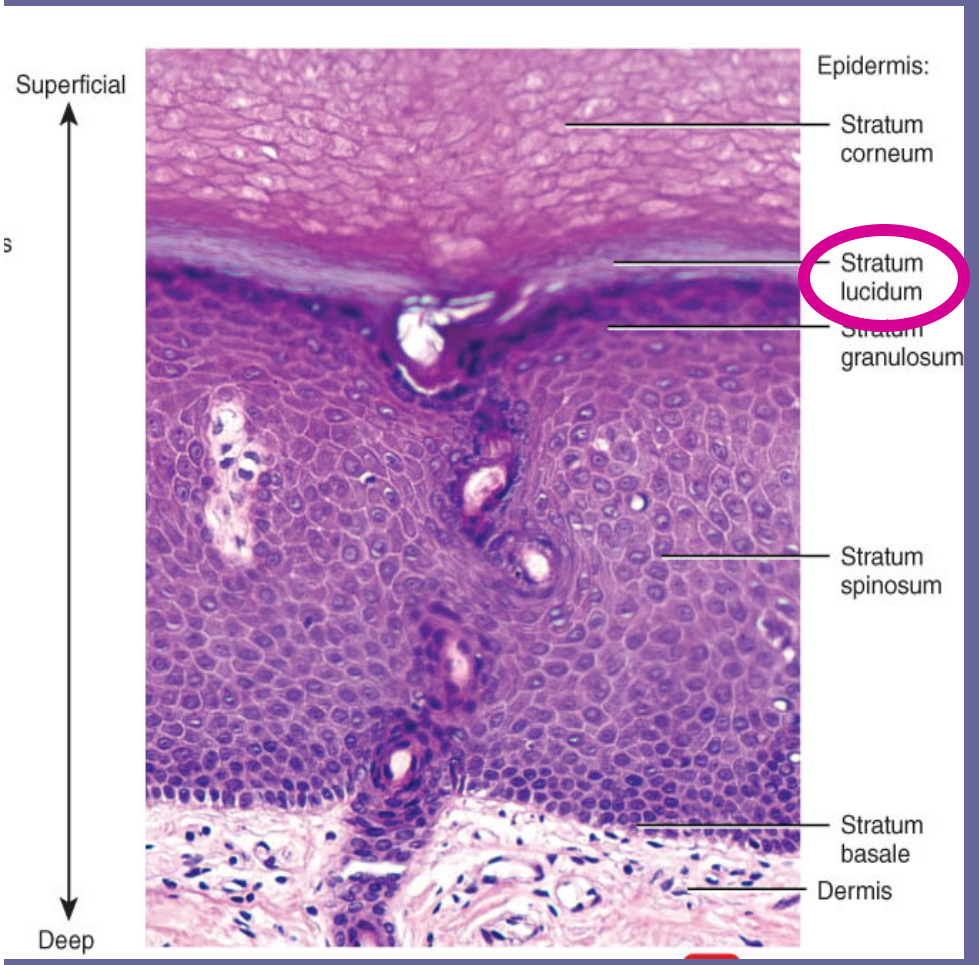

- present only in the fingers tips, palms of the hands, and soles of the feet.
- Three to five layers of clear, flat, dead cells
- Contains precursor of keratin

Stratum Corneum

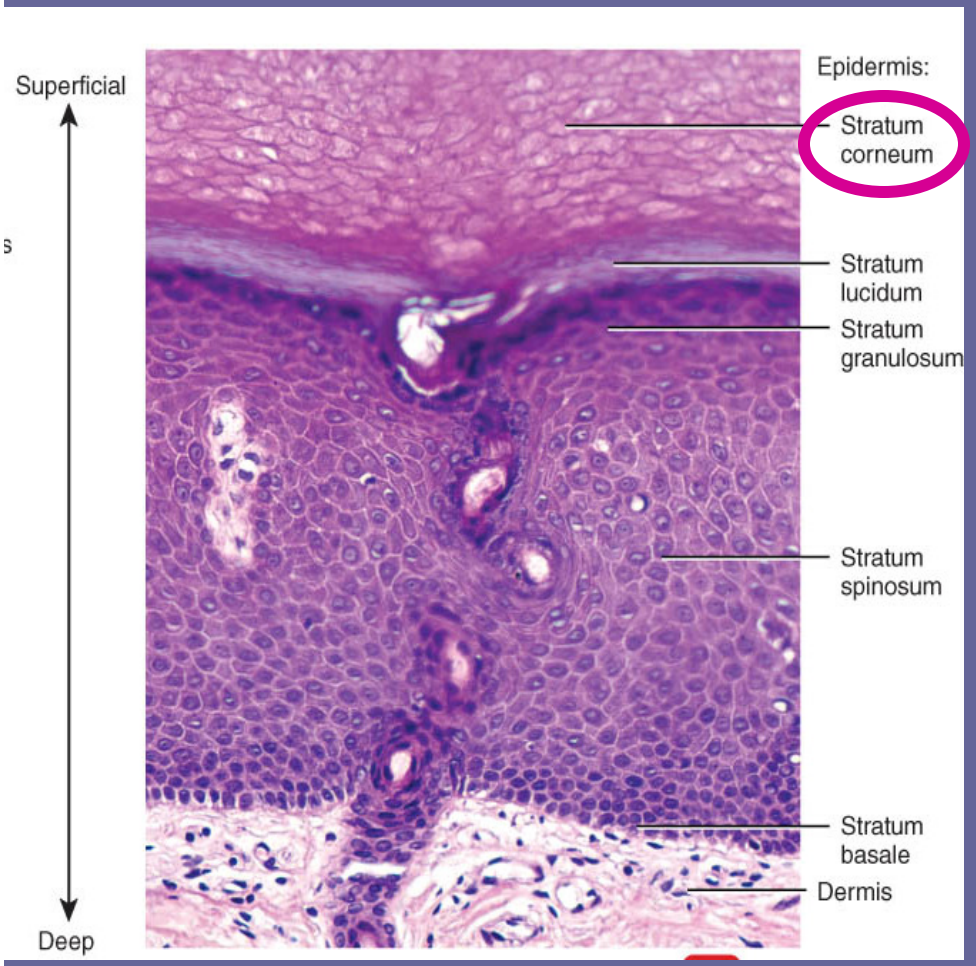

- 25 to 30 layers of flat dead cells filled with keratin and surrounded by lipids
  - continuously shed
- Barrier to light, heat, water, chemicals & bacteria
- Lamellar granules in this layer make it water-repellent.
- Where *callus*, an abnormal thickening of the epidermis, is formed.

Keratinization and Growth of the Epidermis

- Stem cells divide to produce keratinocytes
- As keratinocytes are pushed up towards the surface, they fill with keratin
  - *Keratinization* is replacement of cell contents with the protein keratin; occurs as cells move to the skin surface over 2-4 weeks.
- Epidermal growth factor (EGF) and other hormone-like proteins play a role in epidermal growth.
- Table 5.1 presents a summary of the features of the epidermal strata.

Dermis

- Connective tissue layer composed of collagen & elastic fibers, fibroblasts, macrophages & fat cells
- Contains hair follicles, glands, nerves & blood vessels
- Two major regions of dermis
  - papillary region
  - reticular region

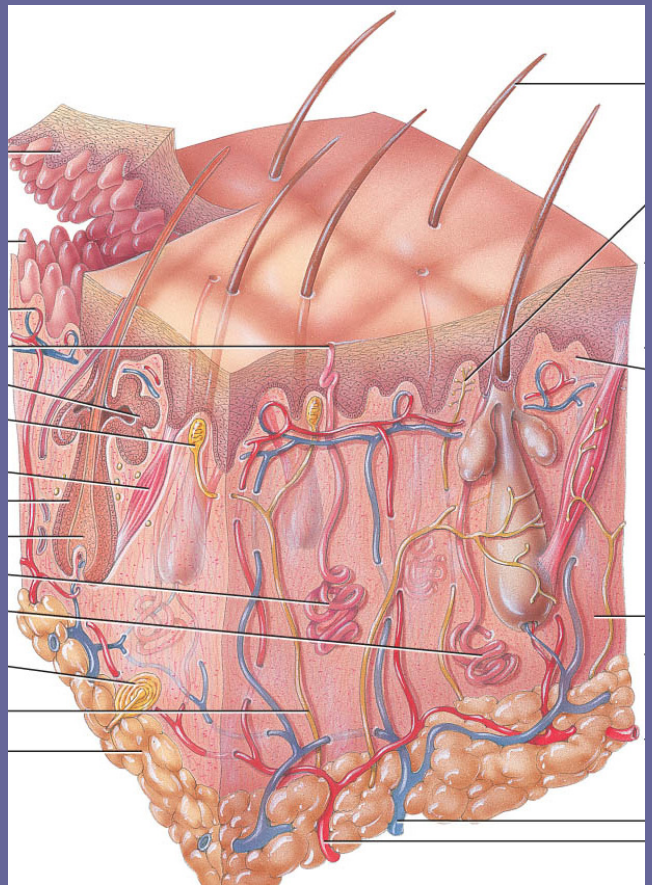

Dermis - Papillary Region

- Top 20% of dermis
- Finger like projections are called dermal papillae
  - anchors epidermis to dermis
  - contains capillaries that feed epidermis
  - contains Meissner's corpuscles (touch) & free nerve endings for sensations of heat, cold, pain, tickle, and itch

Dermis - Reticular Region

- Dense irregular connective tissue
- Contains interlacing collagen and elastic fibers
- Packed with oil glands, sweat gland ducts, fat & hair follicles
- Provides strength, extensibility & elasticity to skin
  - stretch marks are dermal tears from extreme stretching
- Epidermal ridges form in fetus
  - fingerprints are left by sweat glands open on ridges
  - increase grip of hand

Tattoos

- Tattooing is a permanent coloration of the skin in which a foreign pigment is injected into the dermis.

Skin Color Pigments

- The wide variety of colors in skin is due to three pigments - melanin, carotene, and hemoglobin (in blood in capillaries) - in the dermis.

Accessory Structures of Skin

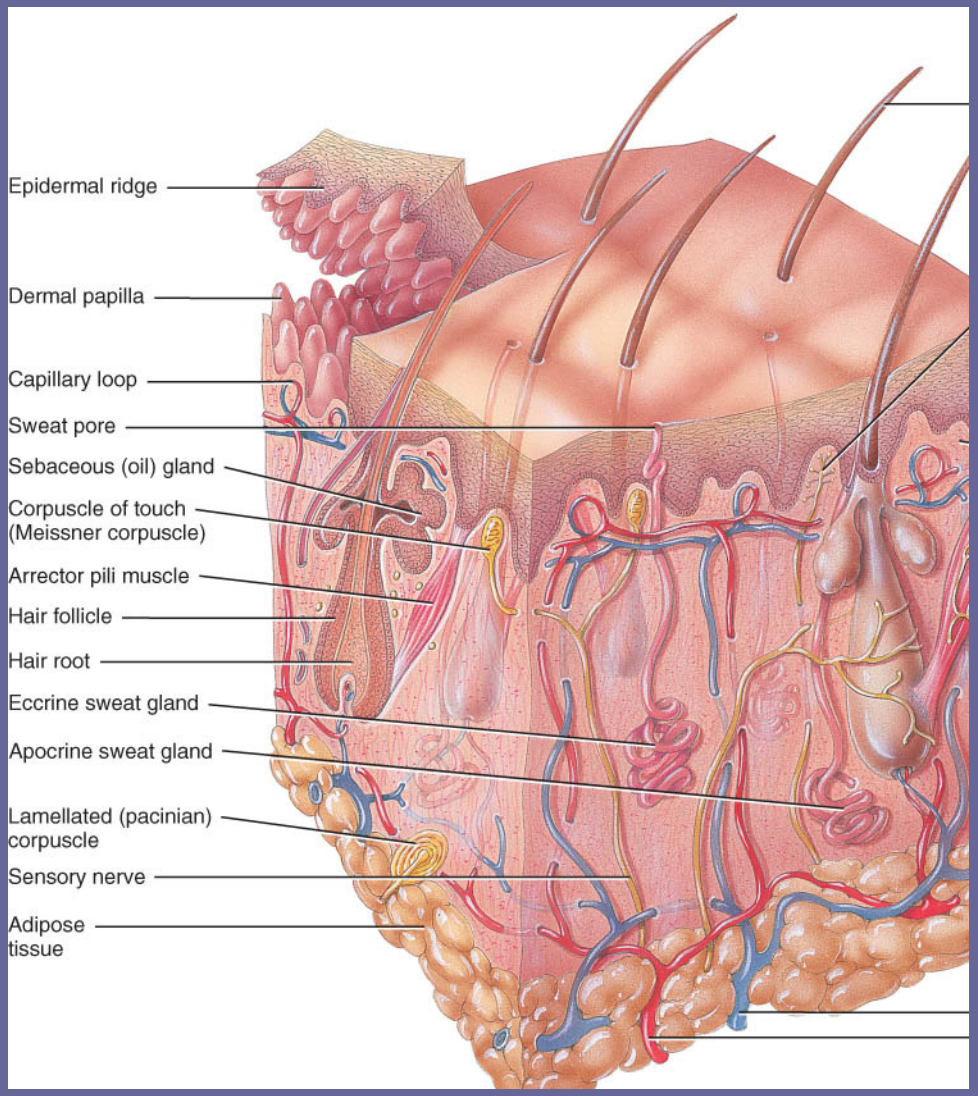

- develop from the embryonic epidermis
- Cells sink inward during development to form:
  - hair
  - oil & sweat glands
  - nails

HAIR

- *Hairs*, or pili, are present on most skin surfaces except the palms, palmar surfaces of the digits, soles, and plantar surfaces of the digits.

- Hair consists of
  - a *shaft* above the surface
  - a *root* that penetrates the dermis and subcutaneous layer
  - the *cuticle*
  - a *hair follicle*

- New hairs develop from cell division of the matrix in the bulb.

Structure of Hair

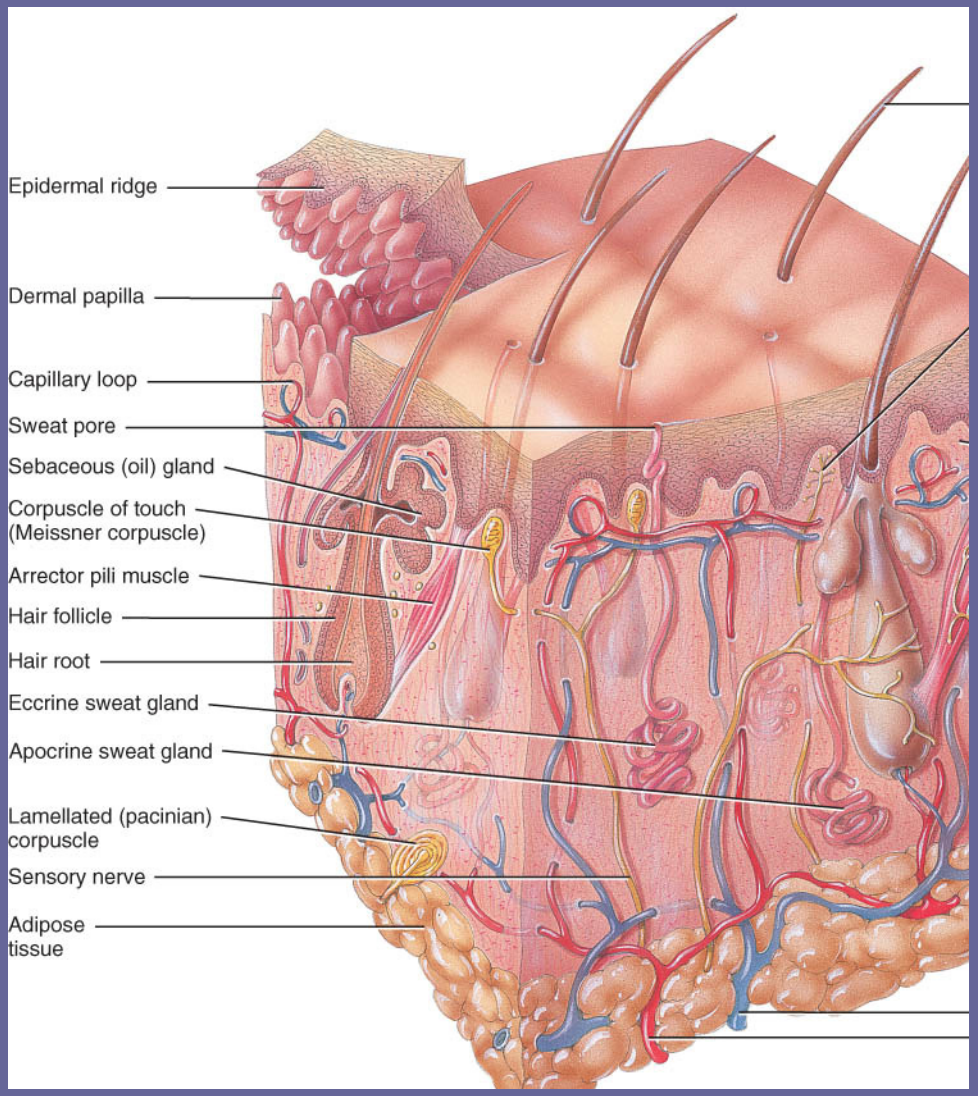

- Shaft -- visible
- Root -- below the surface
- Follicle surrounds root
  - external root sheath
  - internal root sheath
  - base of follicle is bulb
    - blood vessels
    - germinal cell layer

Structure of Hair

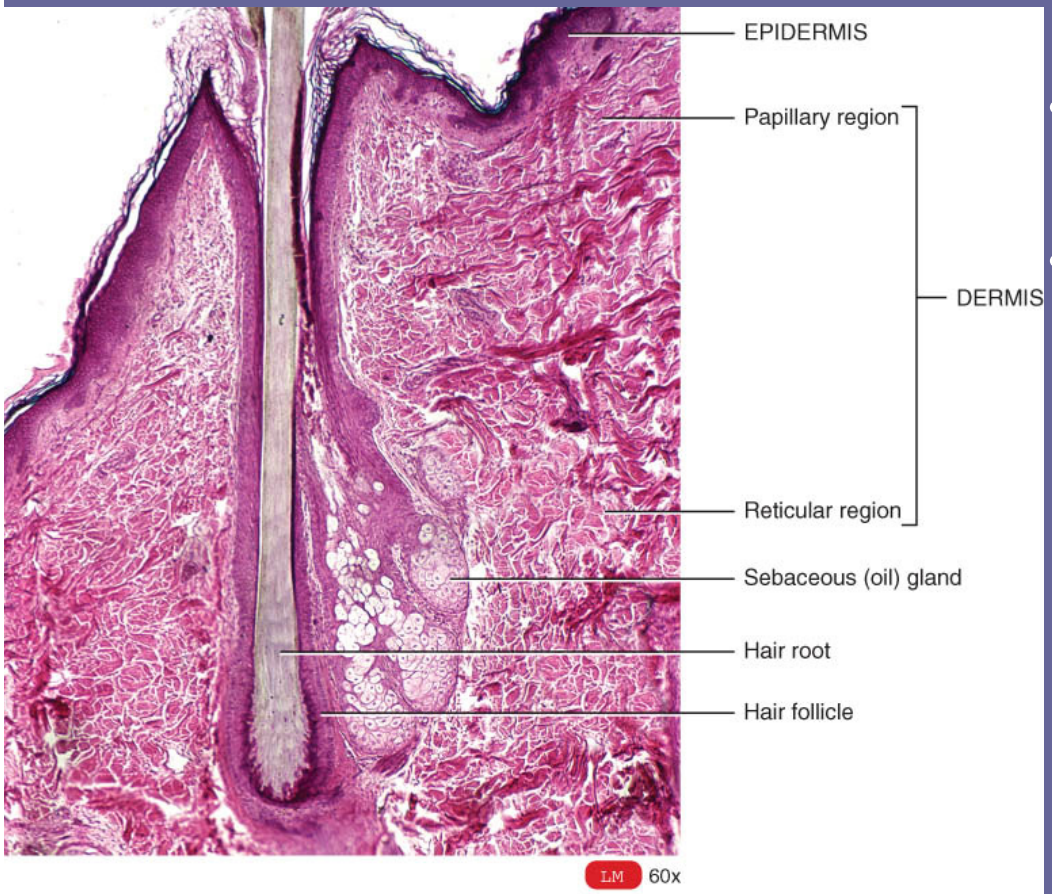

(b) Sectional view of skin

- Shaft -- visible
- Root -- below the surface
- Follicle surrounds root
  - external root sheath
  - internal root sheath
  - base of follicle is bulb
    - blood vessels
    - germinal cell layer

Structure of Hair

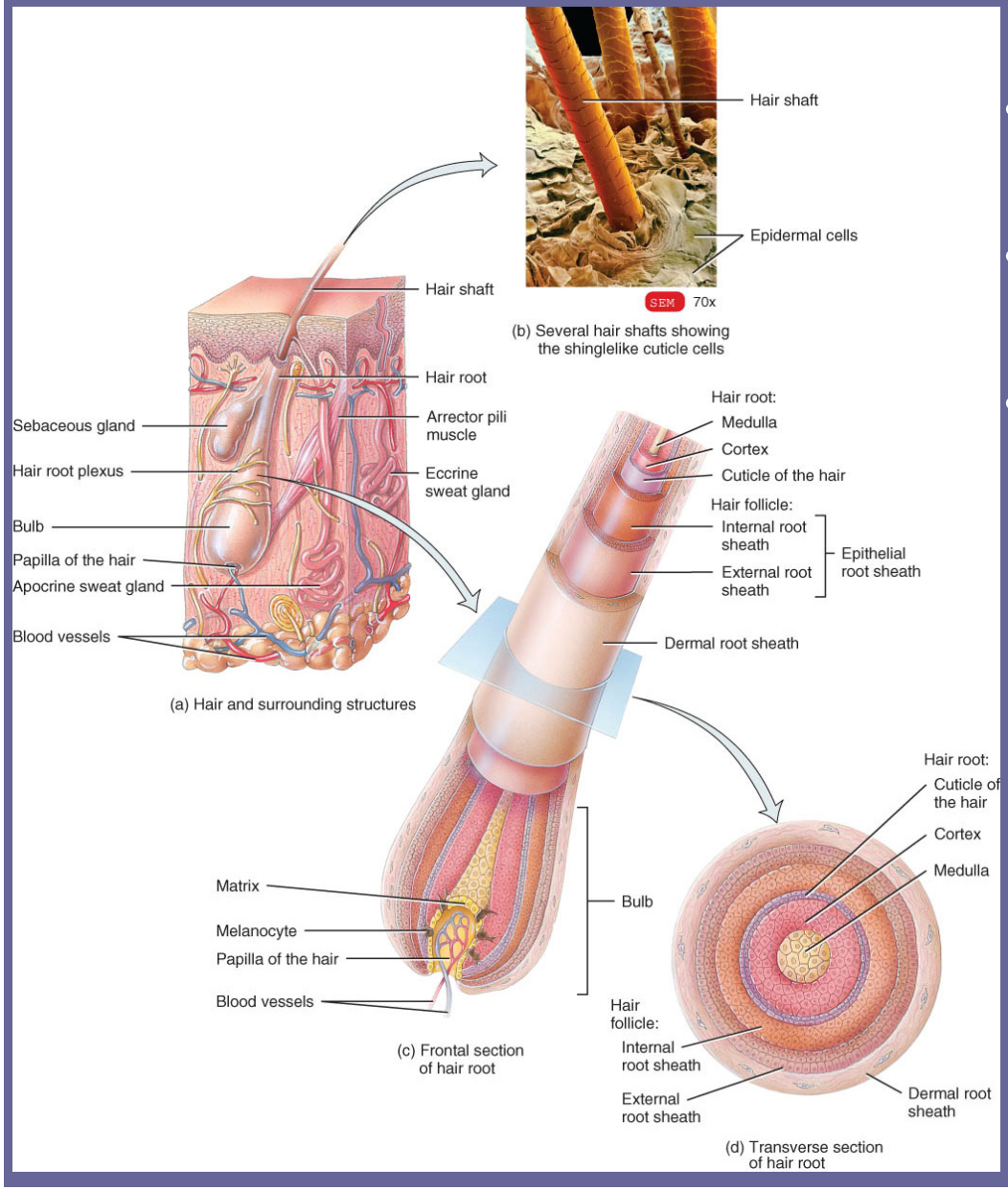

- Shaft -- visible
- Root -- below the surface
- Follicle surrounds root
  - external root sheath
  - internal root sheath
  - base of follicle is bulb
    - blood vessels
    - germinal cell layer

Hair Related Structures

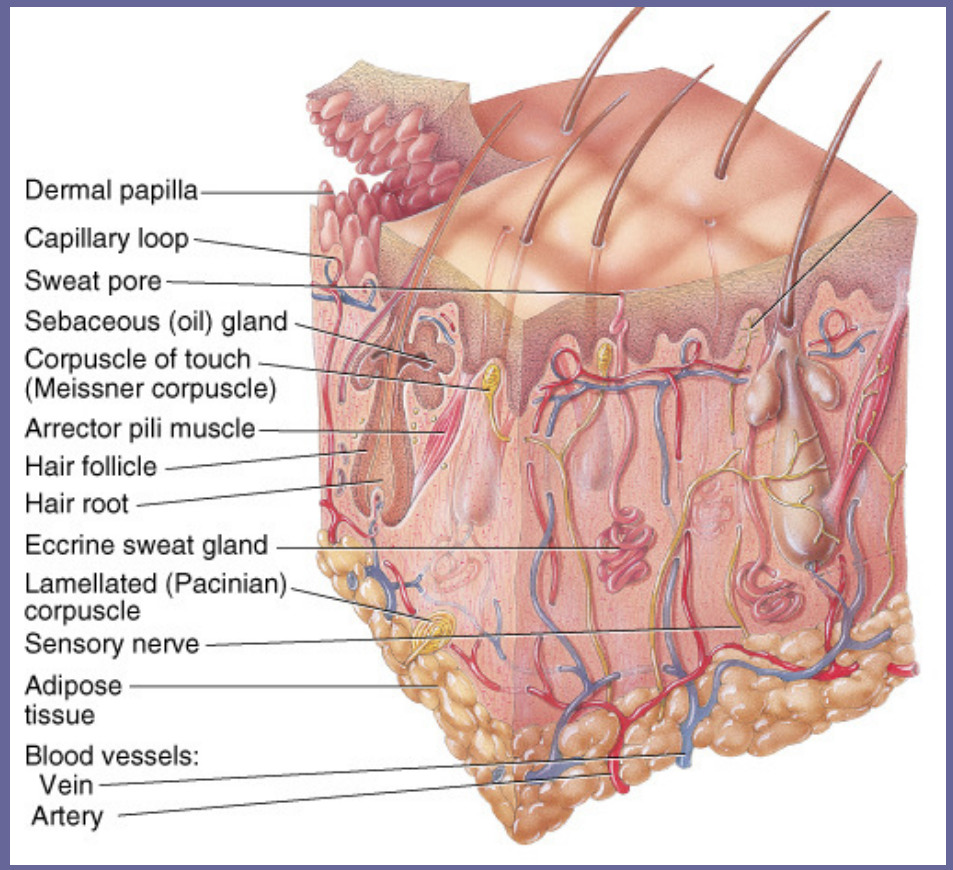

- Arrector pili
  - smooth muscle in dermis contracts with cold or fear.
  - forms goosebumps as hair is pulled vertically
- Hair root plexus
  - detect hair movement
- sebaceous (oil) glands

Hair Growth

- The hair growth cycle consists of a growing stage and a resting stage.
  - Growth cycle = growth stage & resting stage
    - Growth stage
      - lasts for 2 to 6 years
      - matrix cells at base of hair root producing length
    - Resting stage
      - lasts for 3 months
      - matrix cells inactive & follicle atrophies
  - Old hair falls out as growth stage begins again
    - normal hair loss is 70 to 100 hairs per day

Hair Color

- Hair color is due primarily to the amount and type of melanin.
- Graying of hair occurs because of a progressive decline in tyrosinase.
  - Dark hair contains true melanin
  - Blond and red hair contain melanin with iron and sulfur added
  - Graying hair is result of decline in melanin production
  - White hair has air bubbles in the medullary shaft
- Hormones influence the growth and loss of hair (Clinical applications).

Functions of Hair

- Prevents heat loss
- Decreases sunburn
- Eyelashes help protect eyes
- Touch receptors (hair root plexus) senses light touch

Glands of the Skin

- Specialized exocrine glands found in dermis
- Sebaceous (oil) glands
- Sudiferous (sweat) glands
- Ceruminous (wax) glands
- Mammary (milk) glands

Sebaceous (oil) glands

- *Sebaceous (oil) glands* are usually connected to hair follicles; they are absent in the palms and soles
- Produce sebum
    - contains cholesterol, proteins, fats & salts
    - moistens hairs
    - waterproofs and softens the skin
    - inhibits growth of bacteria & fungi (ringworm)
- Acne
  - bacterial inflammation of glands
  - secretions are stimulated by hormones at puberty

Sudoriferous (sweat) glands

Eccrine sweat glands (most areas of skin)

- regulate body temperature through evaporation (perspiration)
- help eliminate wastes such as urea.

Apocrine sweat glands (skin of the axilla, pubis, and areolae)

- secretions are more viscous

Ceruminous Glands

- *Ceruminous glands*
  - produce a waxy substance called cerumen.
  - found in the external auditory meatus
  - barrier for entrance of foreign bodies

Structure of Nails

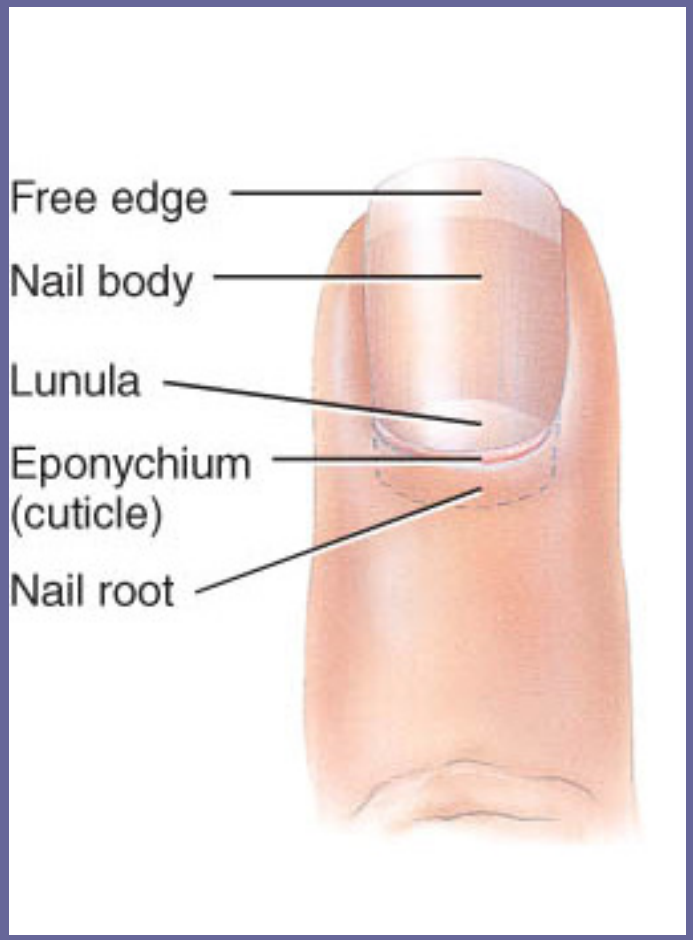

- Tightly packed keratinized cells
- Nail body
  - visible portion pink due to underlying capillaries
  - free edge appears white
- Nail root
  - buried under skin layers
  - lunula is white due to thickened stratum basale
- Eponychium (cuticle)
  - stratum corneum layer

TYPES OF SKIN

- Thin skin
  - covers all parts of the body except for the palms and palmar surfaces of the digits and toes.
  - lacks epidermal ridges
  - has a sparser distribution of sensory receptors than thick skin.
- Thick skin (0.6 to 4.5 mm)
  - covers the palms, palmar surfaces of the digits, and soles
  - features a stratum lucidum and thick epidermal ridges
  - lacks hair follicles, arrector pili muscles, and sebaceous glands, and has more sweat glands than thin skin.

FUNCTIONS OF SKIN -- thermoregulation

- Perspiration & its evaporation
  - lowers body temperature
  - flow of blood in the dermis is adjusted
- Exercise
  - in moderate exercise, more blood brought to surface helps lower temperature
  - with extreme exercise, blood is shunted to muscles and body temperature rises
- Shivering and constriction of surface vessels
  - raise internal body temperature as needed

FUNCTIONS OF SKIN

- *blood reservoir*
  - extensive network of blood vessels

- *protection* - physical, chemical and biological barriers
  - tight cell junctions prevent bacterial invasion
  - lipids released retard evaporation
  - pigment protects somewhat against UV light
  - Langerhans cells alert immune system

- *cutaneous sensations*
  - touch, pressure, vibration, tickle, heat, cold, and pain arise in the skin

FUNCTIONS OF SKIN

- *Synthesis of Vitamin D*
  - activation of a precursor molecule in the skin by UV light
  - enzymes in the liver and kidneys modify the activated molecule to produce calcitriol, the most active form of vitamin D.
  - necessary vitamin for absorption of calcium from food in the gastrointestinal tract

- *excretion*
  - 400 mL of water/day, small amounts salt, CO2, ammonia and urea

Transdermal Drug Administration

- method of drug passage across the epidermis and into the blood vessels of the dermis
  - drug absorption is most rapid in areas where skin is thin (scrotum, face and scalp)
- Examples:
  - nitroglycerin (prevention of chest pain from coronary artery disease)
  - scopolamine (motion sickness)
  - estradiol (estrogen replacement therapy)
  - nicotine (stop smoking alternative)

Photodamage

- Ultraviolet light (UVA and UVB) both damage the skin
- Acute overexposure causes sunburn
- DNA damage in epidermal cells can lead to skin cancer
- UVA produces oxygen free radicals that damage collagen and elastic fibers and lead to wrinkling of the skin

DISORDERS: HOMEOSTATIC IMBALANCES

- *Skin cancer* can be caused by excessive exposure to sunlight.
- Among the risk factors for skin cancer are skin type, sun exposure, family history, age, and immunologic status.

Skin Cancer

- 1 million cases diagnosed per year
- 3 common forms of skin cancer
  - basal cell carcinoma (rarely metastasize)
  - squamous cell carcinoma (may metastasize)
  - malignant melanomas (metastasize rapidly)
    - most common cancer in young women
    - arise from melanocytes ----life threatening
    - key to treatment is early detection watch for changes in symmetry, border, color and size
    - risks factors include-- skin color, sun exposure, family history, age and immunological status

Burns

- Tissue damage from excessive heat, electricity, radioactivity, or corrosive chemicals that destroys (denatures) proteins in the exposed cells is called a *burn.*
- Generally, the systemic effects of a burn are a greater threat to life than are the local effects.
- The seriousness of a burn is determined by its depth, extent, and area involved, as well as the person's age and general health. When the burn area exceeds 70%, over half of the victims die.

Burns

- Destruction of proteins of the skin
  - chemicals, electricity, heat
- Problems that result
  - shock due to water, plasma and plasma protein loss
  - circulatory & kidney problems from loss of plasma
  - bacterial infection

- Two methods for determining the extent of a burn are the rule of nines and the Lund-Bowder method (Figure 5.10).

Burns

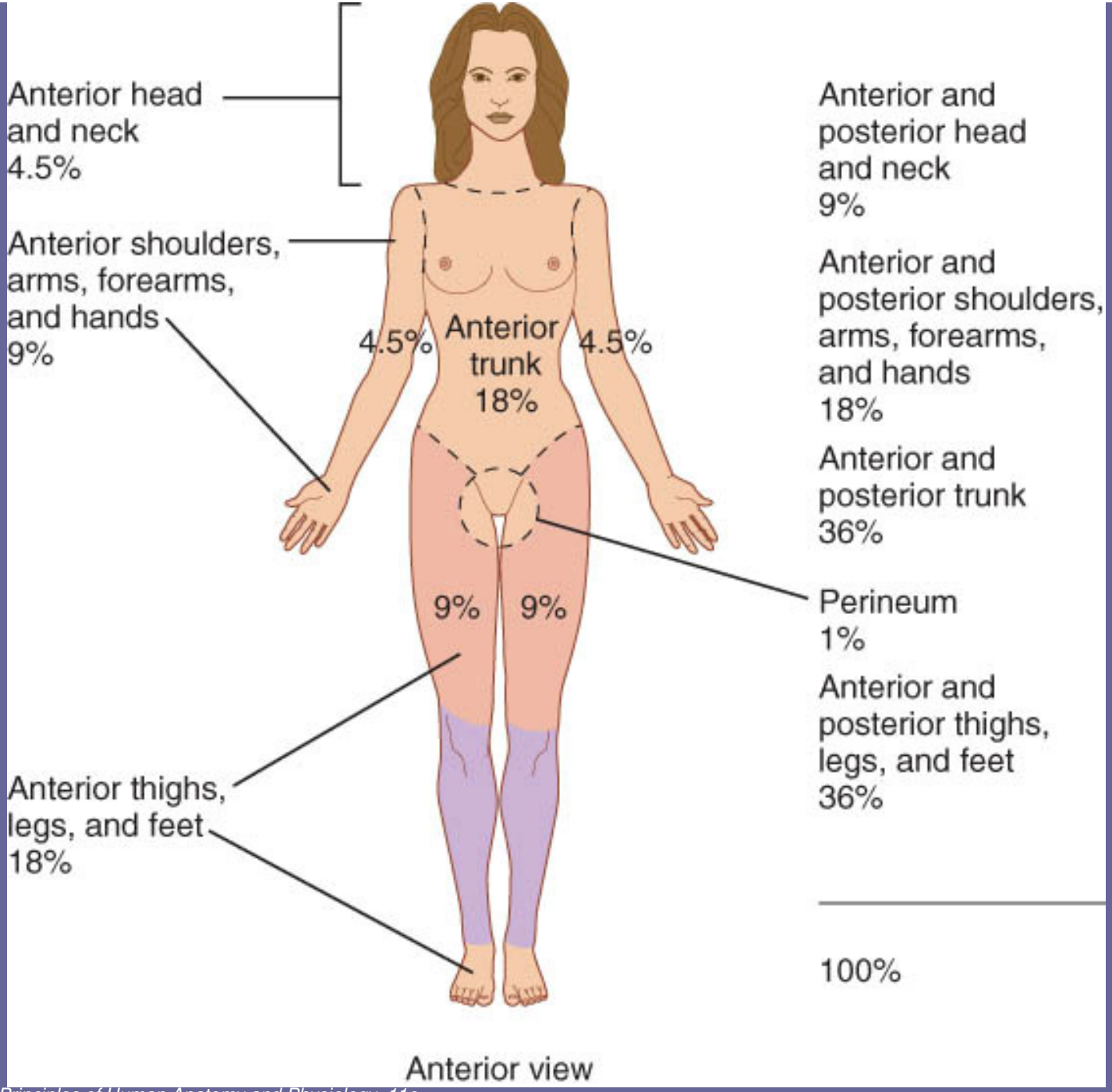
Anterior head and neck 4.5%
Anterior shoulders, arms, forearms, and hands 9%
4.5%
Anterior trunk 18%
4.5%
9%
9%
Anterior thighs, legs, and feet 18%
Anterior and posterior head and neck 9%
Anterior and posterior shoulders, arms, forearms, and hands 18%
Anterior and posterior trunk 36%
Perineum 1%
Anterior and posterior thighs, legs, and feet 36%
100%
Anterior view

Types of Burns

- First-degree
  - only epidermis (sunburn)
- Second-degree burn
  - destroys entire epidermis & part of dermis
  - fluid-filled blisters separate epidermis & dermis
  - epidermal derivatives are not damaged
  - heals without grafting in 3 to 4 weeks & may scar
- Third-degree or full-thickness
  - destroy epidermis, dermis & epidermal derivatives
  - damaged area is numb due to loss of sensory nerves

Burns

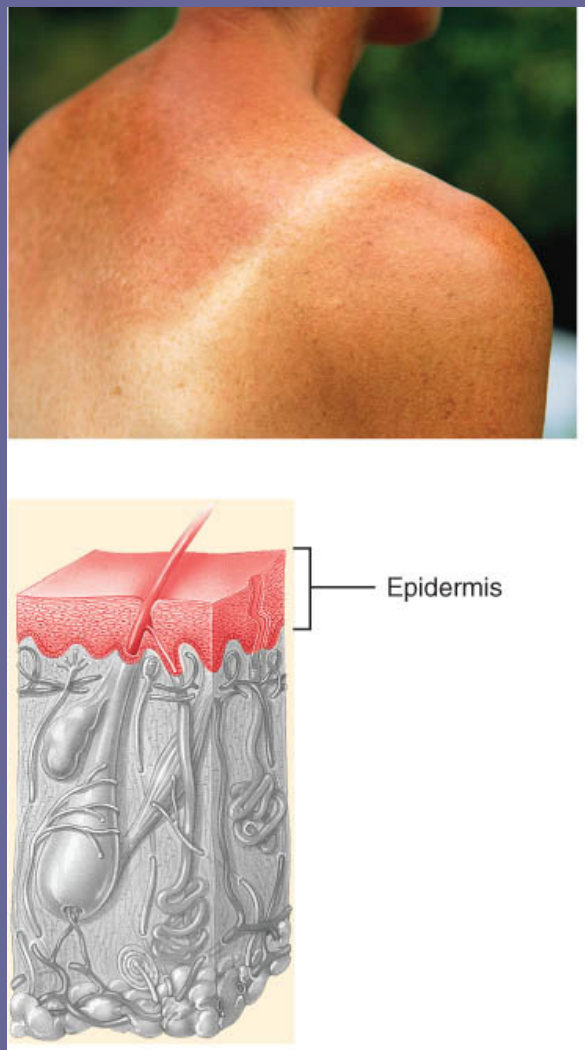

(a) First-degree burn (sunburn)

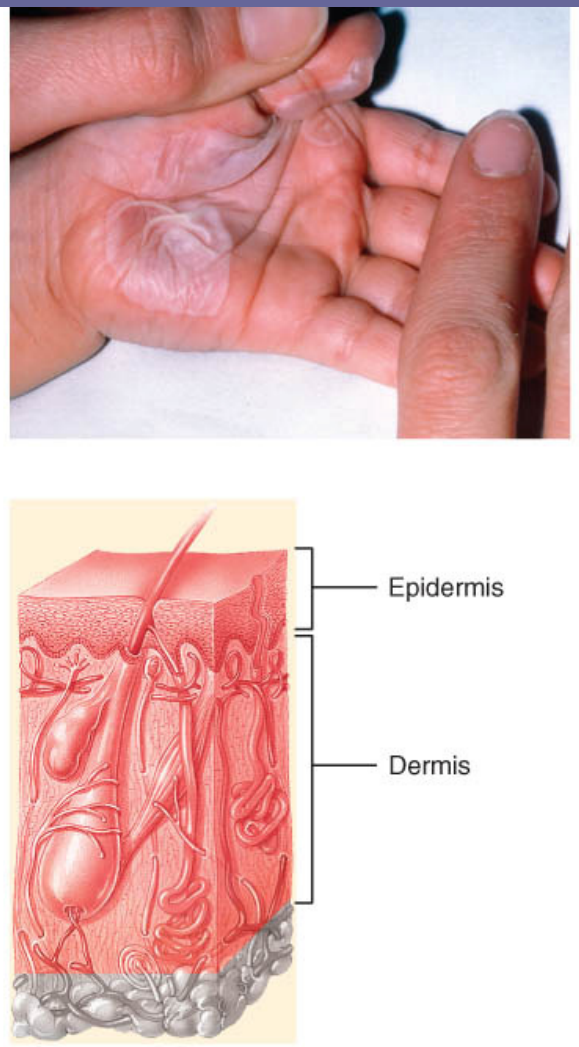

(b) Second-degree burn (note the blister)

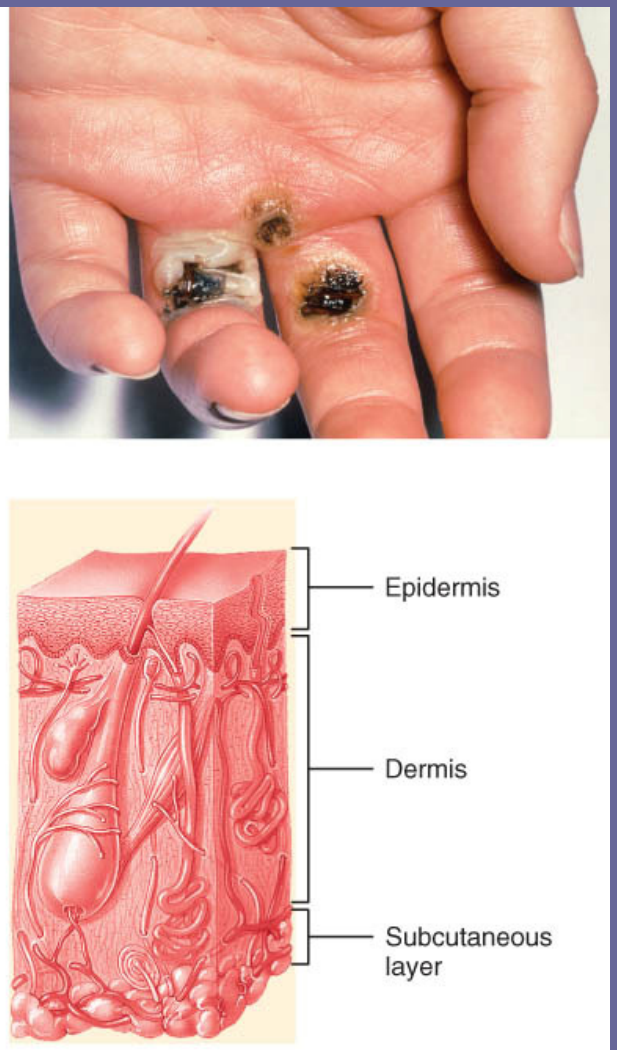

(c) Third-degree burn

end